

# Sacroiliac Joint as a Pain Generator in Patients With Lumbar Disc Herniation

## Lomber Disk Hernili Hastalarda Ağrı Kaynağı Olarak Sakroiliak Eklem

Mehmet Ali TAŞKAYNATAN, Kutay TEZEL, İltekin DUMAN, Ahmet ÖZGÜL, Arif Kenan TAN  
Gulhane Military Medical Academy, Department of Physical Medicine and Rehabilitation, Ankara, Turkey

### Summary

**Objective:** To investigate the effect of the fluoroscopy guided sacroiliac joint (SIJ) injection in patients with lumbar disc herniation, which was determined with magnetic resonance imaging, and sacroiliac dysfunction which was identified with clinical examination.

**Materials and Methods:** Patients with low back pain (LBP) lasting more than four weeks, radiating into the thigh or lower limb were eligible for the study. In these patients, when physical examination showed that SIJ might be the pain generator, a SIJ corticosteroid and local anesthetic injection was initially performed. The patients were assessed one hour, and two weeks after the injection.

**Results:** Sacroiliac joint injection was performed on 14 patients selected from 60 patients. In 12 patients (20%), source of LBP was attributed to SIJ. In these patients, pain severity decreased more than %75 after one or two injections. A second SIJ injection was performed in two patients.

**Conclusion:** Clinicians should take into account the possibility of non-spinal pain generators even if patients presented with a specific diagnosis. In addition, a fluoroscopy guided SIJ corticosteroid and local anesthetic injection can be effective in the diagnosis and treatment of these patients. *Türk J Phys Med Rehab 2012;58:26-8.*

**Key Words:** Sacroiliac joint, low back pain, lumbar disc herniation, intervention, epidural steroid injection

### Özet

**Amaç:** Manyetik rezonans görüntüleme ile lomber disk hernisi saptanan hastalarda, sakroiliak eklem (SİE) kaynaklı ağrı için floroskopi rehberliğinde SİE kortikosteroid ve lokal enjeksiyon sonuçlarının belirlenmesi.

**Gereç ve Yöntem:** Dört haftadan uzun süre devam eden uyluğa veya alt ekstremiteye yayılan bel ağrısı olan hastalar çalışma için uygun görüldü. Bu hastalardan fizik muayene sırasında SİE'nin ağrı kaynağı olabileceği gösterilenlere, başlangıçta SİE'ye kortikosteroid ve lokal anestetik enjeksiyonu uygulandı. Hastalar enjeksiyondan bir saat ve iki hafta sonra değerlendirildi.

**Bulgular:** Altmış hasta içerisinde seçilen 14 hastaya SİE enjeksiyonu uygulandı. On iki (%20) hastada bel ağrısı kaynağı SİE'ye atfedildi. Bu hastalarda bir veya iki enjeksiyon sonrasında ağrı düzeyi %75'den fazla düştü. İki hastada ikinci enjeksiyon uygulandı.

**Sonuç:** SİE, lomber disk hernisi ile refere edilen hastalarda başlıca veya iştirak eden ağrı kaynağı olabilir. Anamnez ve fizik muayene bu olasılığı gösterdiğinde tanısal ve tedavi edici SİE kortikosteroid ve lokal anestetik enjeksiyonu ilk tedavi olarak uygulanabilir. *Türk Fiz Tıp Rehab Derg 2012;58:26-8.*

**Anahtar Kelimeler:** Sakroiliak eklem, bel ağrısı, lomber disk hernisi, girişimsel, epidural steroid enjeksiyonu

### Introduction

Sacroiliac joint (SIJ) is one of the common sources of chronic low back pain (LBP) and its prevalence varies from 15% to 30% based on the clinical evaluations (1). Variety in symptoms and the lack of a gold standard diagnostic tool make the diagnosis

difficult. A reference standard for diagnosing SIJ pain was suggested in 1994 by the Interventional Association Society for the Study of Pain (IASP). IASP's three diagnostic criteria were: pain localized in the region of the SIJ, positive results of clinical tests stressing the joint to provoke the patient's pain, and the relief of pain with a selective anesthetic injection to SIJ (2).

In this study, we aimed to investigate the effect of the fluoroscopy guided SIJ injection in patients with lumbar disc herniation (LDH), which was determined with magnetic resonance imaging (MRI) and sacroiliac dysfunction, which was identified with clinical examination.

## Material and Methods

Between January and June 2008, patients, who attended our interventional musculoskeletal pain unit for an epidural steroid injection to the corresponding LDH level and who were fulfilling the following inclusion criteria, were examined for a possible pain generator originating from the SIJ: 1. Persistent radicular LBP lasting  $\geq 4$  weeks despite an appropriate conservative treatment; 2. At least one level LDH, which was shown on a recent MRI. The patients were split into two Groups: 1. SIJ injection group, 2. epidural steroid injection group. The flowchart of the patients is given in Figure 1. All patients were older than 18 years. The study was approved by our institutional local ethics committee and written informed consent was obtained from each patient.

The patients who had at least three positive results from the following tests; Yeoman's, Gaenslen's, FABER, compression and the sacral thrust tests, were considered that SIJ was the possible pain generator (3,4). A sacroiliac radiograph was ordered for these patients and a SIJ local anesthetic and corticosteroid injection was administered under fluoroscopy guidance.

The patients, who did not show positive response to three sacroiliac provocation tests, were included in the transforaminal epidural corticosteroid injection group. We followed up these patients on daily routine basis.

Injection technique: The injection was made by using fluoroscopy guidance. The patient was placed in the prone position on the fluoroscopy table. The image intensifier was rotated to identify SIJ clearly. The skin under and around the

marked site was prepared and draped in standard, sterile fashion, utilizing a providone iodine based skin prep. The soft tissue was anesthetized using 2 ml of 1% prilocaine hydrochloride. Then, a 22-gauge, 3.5-inch spinal needle was inserted into SIJ space under fluoroscopy control. One-two ml of contrast material (omnipaque 300) was injected to confirm a proper arthrogram pattern (Figure 2) and to avoid vascular uptake or inadvertently distribution of medication to the sacral plexus. Then, a mixture of 1 ml of betamethasone acetate (6 mg) and 1 ml of 2% prilocaine hydrochloride were injected into the SIJ. After the injection, complications and visual analogue scale (VAS) pain scores were recorded.

The intensity of pain was evaluated by using a 10 cm visual analog scale (VAS) ranging from 0 (no pain) to 10 (excruciating pain). The pain was evaluated just before the injection, one hour after the injection, and at the second week. The therapeutic goal was to achieve a decrease in VAS score by 75% or more at the second week after the injection. A second injection was performed in patients with 50-75% pain relief and these patients were reassessed after two weeks. If the VAS scores did not decrease significantly ( $< 50\%$ ), the patients were included in the transforaminal epidural corticosteroid injection group (Figure 1) (5).

## Statistics

Statistical analysis was performed using the Statistical Package for Social Sciences (SPSS) program version 11.0 for Windows (SPSS Inc., Chicago, IL). For descriptive data, mean $\pm$ standard deviation notation was used. Comparisons between the groups were made using the Mann-Whitney tests. The results were analyzed by the Friedman test for repeated measures and the Wilcoxon signed-rank test for comparison of the data within the groups. A p-value of less than 0.05 was considered to be significant.

## Results

SIJ steroid and local anesthetic injection was performed in 14 patients selected from 60 patients. At the second week, two patients were excluded from SIJ injection group due to unsatisfactory pain relief (improvement less than 50%) (Figure 1).

In SIJ injection group (12 patients), the mean age of the patients was  $36,8 \pm 14,9$  years. Seven patients were female and five were male. In seven patients left SIJ and in five patients right SIJ injection was performed. The mean VAS pain score was  $7 \pm 1,2$  at baseline;  $4,1 \pm 1,8$  at one hour after the injection;  $3,3 \pm 1,6$  at the second week;  $2,8 \pm 0,9$  at the third month. The change in VAS scores was statistically significant ( $p < 0,001$ ).

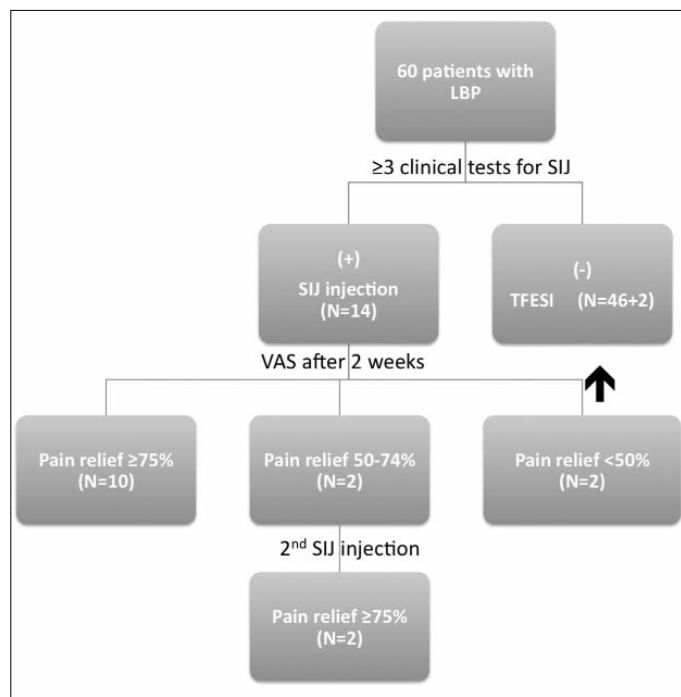


Figure 1. The flowchart of the patients.  
 LBP: low back pain, SIJ: sacroiliac joint,  
 TFESI: transforaminal epidural steroid injection.

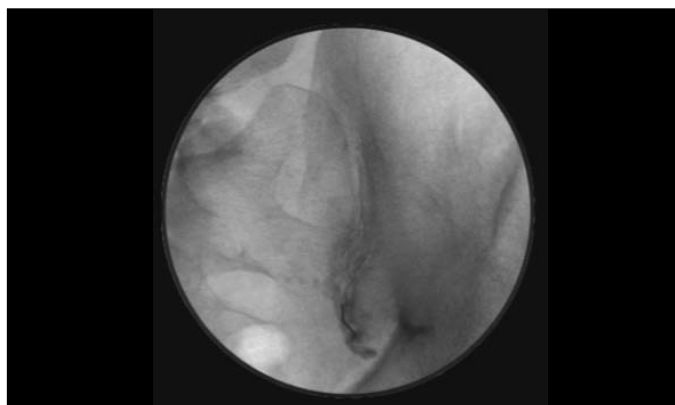


Figure 2. A proper sacroiliac joint arthrogram pattern obtained after contrast injection.

A second SIJ injection was performed in two patients due to improvement less than 75% but more than 50%. We obtained  $\geq 75\%$  pain relief on these patients at follow-up. As a result, 12 in 60 patients (20%) had SIJ pain.

Distribution of intervertebral disc herniations was as follows: L2-3 in one patient, L3-4 in two patients, L4-5 in five patients, and L5-S1 in four patients. Difference in distributions of intervertebral disc herniations between the groups (SIJ and epidural injection groups) was not statistically significant ( $p > 0.05$ ).

In these patients, we could not find any abnormality in their SIJ on plain radiographies. Neither side effect, nor complication was observed.

## Discussion

Although, there are many causes of LBP, lumbar disc herniation is the most prominent cause and in many parts of the world, it takes up so much time of clinicians (6). Therefore, the role of SIJ in LBP may be overlooked. In the literature, there are a number of studies that showed the pain, originating from the SIJ and other sources may produce referred pain in the buttock, groin and lower extremities (7-9). Therefore, SIJ still keeps its place in the differential diagnosis even in the clinical pictures with a radicular LBP and LDH on MRI.

Sembrano and Polly (10) found that 82% of patients referred to a spine surgery clinic for LBP had spine pathology, but only 65% had spine-only pathology. They reported the frequency of SIJ pathology as 14.5% but they did not document the differences between radicular and non-radicular groups. As they mentioned in the paper, it should be taken into account that the results were obtained in the setting of a spine surgeon's clinic. The frequency of SIJ pathology in our patient population (20%) probably did not reflect the exact rate because we did not make diagnostic sacroiliac injections to all patients who were included in the study. We rather preferred to make the injections to confirm the diagnosis and to evaluate the effect of corticosteroid and local anesthetic injection on the patients with a possible SIJ pain.

Chronic persistent LBP is commonly linked with positive disc findings on CT or MRI scans. However these imaging techniques are not always helpful to physicians because they have a poor correlation with clinical signs (11). Some investigators have revealed disc protrusion or herniation on post-mortem examination in 40% of patients with no history of sciatic pain. Thirty-five percent of asymptomatic individuals demonstrated myelographic abnormalities and up to 60% had MRI findings (12). Furthermore, the diagnostic accuracy of the tissue origin of chronic LBP and referred lower extremity symptoms based on clinical criteria are about 19-24% (13). In the present study, most of the patients in SIJ injection group (nine of twelve patients) had a lower segment lumbar disc herniation, which could cause pain in buttock. Therefore, it was not easy to say that the pain generator was only SIJ despite the improvement in pain more than 75% after one or two injections. We did not try to bring out the SIJ-only patients. This was one of the limitations of the study. On the other hand, in lumbar disc pathologies, dispersion of the load equally to lower segments like SIJ may be disrupted and this may lead to increase in local stress in that region (14). Therefore, it sounds possible to postulate that SIJ pain may evolve secondarily to a clinical picture like LDH. A study with a control group that is designed to investigate the frequency of SIJ pathology in patients with LDH may confirm this postulation.

In fact, the diagnosis of SIJ dysfunction can be difficult. Since the clinical manifestations of the SIJ syndrome are diverse, the diagnosis cannot be based on patient's description of

symptoms. CT scanning (15) and radionuclide imaging (16) play a limited role in the diagnosis of SIJ dysfunction because of their low sensitivity and specificity. The value of pain provocation tests in the diagnosis of SIJ pain is controversial. However, a number of investigators showed that, more than three tests could have a diagnostic value (1,3,11). Therefore, we used those special tests to reveal the possible pain generator. Eventually, 12 patients out of 14 selected from 60 patients achieved a considerable pain relief after corticosteroid and local anesthetic injection(s). In the literature, it is often assumed that an analgesic response to a properly performed diagnostic block is the most reliable method to diagnose SIJ pain (11). However, the corticosteroid which was delivered to the SIJ may also have some effect on the disc pathology. Therefore, it does not seem realistic to attribute all the success of the injection to the correct pain generator like SIJ.

As a result, we suggest that the SIJ could also be a pain generator in patients with a lumbar disc herniation. Our results show that, the clinicians should take into account the possibility of non-spinal pain generators even if the patients presented with a specific diagnosis. In addition, a fluoroscopy guided SIJ corticosteroid and local anesthetic injection can be effective in diagnosis and treatment of these patients.

## Conflict of Interest:

Authors reported no conflicts of interest.

## References

1. Szadek K, van der Wurff P, van Tulder M, Zuurmond W, Perez R. Diagnostic validity of criteria for sacroiliac joint pain: A systematic review. *J Pain* 2009;10:354-68.
2. Merskey H, Bogduk N. Classification of chronic pain: Descriptions of chronic pain syndromes and definitions of pain terms. 2nd ed. Seattle, WA: IASP Press, 1994 p. 190-1.
3. Slipman CW, Sterenfeld EB, Chou LH, Herzog R, Vresilovic E. The predictive value of provocative sacroiliac joint stress maneuvers in the diagnosis of sacroiliac joint syndrome. *Arch Phys Med Rehabil* 1998;79:288-92.
4. Chou LH, Slipman CW, Bhagia SM, Tsaur L, Bhat AL, Isaac Z, et al. Inciting events initiating injection-proven sacroiliac joint syndrome. *Pain Med* 2004;5:26-32.
5. Katz V, Schofferman J, Reynolds J. The sacroiliac joint: a potential cause of pain after lumbar fusion to the sacrum. *J Spinal Disord Tech* 2003;16:96-9.
6. Izi Y, Taskaynatan MA. Management of lower back pain in young Turkish recruits. *Mil Med* 2004;169:824-8.
7. van der Wurff P, Buijs EJ, Groen GJ. Intensity mapping of pain referral areas in sacroiliac joint pain patients. *J Manipulative Physiol Ther* 2006;29:190-5.
8. Slipman CW, Jackson HB, Lipetz JS, Chan KT, Lenrow D, Vresilovic EJ. Sacroiliac joint pain referral zones. *Arch Phys Med Rehabil* 2000;81:334-8.
9. Fortin JD, Aprill CN, Ponthieux B, Pier J. Sacroiliac joint: pain referral maps upon applying a new injection/arthrography technique. Part II: Clinical evaluation. *Spine (Phila Pa 1976)* 1994;19:1483-9.
10. Sembrano J, Polly DJ. How often is low back pain not coming from the back? *Spine* 2009;34:27-32.
11. Foley B, Buschbacher R. Sacroiliac joint pain - Anatomy, biomechanics, diagnosis, and treatment. *Am J Phys Med Rehabil* 2006;85:997-1006.
12. Carragee EJ. Clinical practice. Persistent low back pain. *N Engl J Med* 2005;352:1891-8.
13. Laslett M, McDonald B, Tropp H, Aprill CN, Oberg B. Agreement between diagnoses reached by clinical examination and available reference standards: a prospective study of 216 patients with lumbopelvic pain. *BMC Musculoskelet Disord* 2005;6:28.
14. Taskaynatan MA, Izi Y, Ozgul A, Hazneci B, Dursun H, Kalyon TA. Clinical significance of congenital lumbosacral malformations in young male population with prolonged low back pain. *Spine (Phila Pa 1976)* 2005;30:E210-3.
15. Gevargez A, Groenemeyer D, Schirp S, Braun M. CT-guided percutaneous radiofrequency denervation of the sacroiliac joint. *Eur Radiol* 2002;12:1360-5.
16. Slipman C, Sterenfeld E, Chou L, Herzog R, Vresilovic E. The value of radionuclide imaging in the diagnosis of sacroiliac joint syndrome. *Spine (Phila Pa 1976)* 1996;21:2251-4.