

# A case of transient hemiplegia after cervical transforaminal epidural injection with dexamethasone: What actually happened?

Serdar Kokar , Rekib Sacaklıdır , Savaş Şencan , Osman Hakan Gündüz 

Department of Physical Medicine and Rehabilitation, Division of Pain Medicine, Marmara University Faculty of Medicine, Istanbul, Türkiye

Received: December 11, 2022 Accepted: March 08, 2023 Published online: May 03, 2023

## ABSTRACT

Cervical transforaminal epidural steroid injections (TESIs) have technical difficulties and a risk of complications due to the cervical spine anatomy. A 52-year-old female patient was admitted to our outpatient clinic with complaint of neuropathic pain radiating to her right arm. Right C7 TESI was planned for patient who did not respond to conservative treatment. Immediately after the procedure, flaccid paralysis was detected in the right side and, at the end of 24 h, the patient completely regained her former muscle strength. In conclusion, patient selection for the cervical TESI should be done carefully and kept in mind that transient spinal cord ischemia may develop.

**Keywords:** Cervical pain, complications, epidural injection, fluoroscopy, transient hemiplegia.

Cervical transforaminal epidural steroid injections (TESIs) are interventional procedures used for the treatment of radicular pain secondary to disc herniations.<sup>[1]</sup> The TESI is preferred by some physicians, as it provides a direct and higher concentration of drug delivery to the affected nerve root.<sup>[1]</sup>

Cervical TESIs have technical difficulties and a risk of complications due to the cervical spine anatomy. Major complications, such as spinal cord infarction, epidural hematoma, epidural abscess, vertebrobasilar brain infarcts, spinal cord edema, seizures, high spinal anesthesia, and even death, are seen after cervical TESI.<sup>[2]</sup> Also, neurological deficits lasting >24 h due to spinal cord edema or spinal cord injury (SCI) have been reported in 15 case reports in the literature.<sup>[3]</sup>

Although SCI cases have been described in the literature, the rate of SCI has decreased recently.<sup>[2]</sup> Avoiding the use of particulate steroids, using contrast

materials in imaging methods, and increasing the use of digital subtraction angiography (DSA) may reduce the complication rate. However, the gap between the increase in the number of procedures and the decrease in the complication rate remains unclear.<sup>[2]</sup> Physicians' reluctance to report their complications due to the legal process and the fact that some patients do not give consent for the publication of their data may be some explanations for this gap. In addition, the data on SCI patients who do not need rehabilitation may not be reflected to literature.<sup>[3]</sup> Therefore, it is likely to underestimate the complications seen in cervical TESIs, and more case reports are needed.

Dexamethasone is considered a safe agent and its use is recommended to avoid the risk of complications in cervical epidural injections. In this article, we, for the first time, report a case of hemiplegia lasting less than 24 h after cervical TESI in a female patient.

**Corresponding author:** Rekib Sacaklıdır, MD. Marmara Üniversitesi Tıp Fakültesi, Fiziksel Tıp ve Rehabilitasyon Anabilim Dalı, Ağrı Tıbbi Bilim Dalı, 34899 Pendik, İstanbul, Türkiye.

E-mail: rakipsacakli@hotmail.com

Cite this article as:

Kokar S, Sacaklıdır R, Şencan S, Gündüz OH. A case of transient hemiplegia after cervical transforaminal epidural injection with dexamethasone: What actually happened? Turk J Phys Med Rehab 2023;69(x):i-v. doi: 10.5606/tftrd.2023.12213.

©2023 All right reserved by the Turkish Society of Physical Medicine and Rehabilitation

This is an open access article under the terms of the Creative Commons Attribution-NonCommercial License, which permits use, distribution and reproduction in any medium, provided the original work is properly cited and is not used for commercial purposes (<http://creativecommons.org/licenses/by-nc/4.0/>).



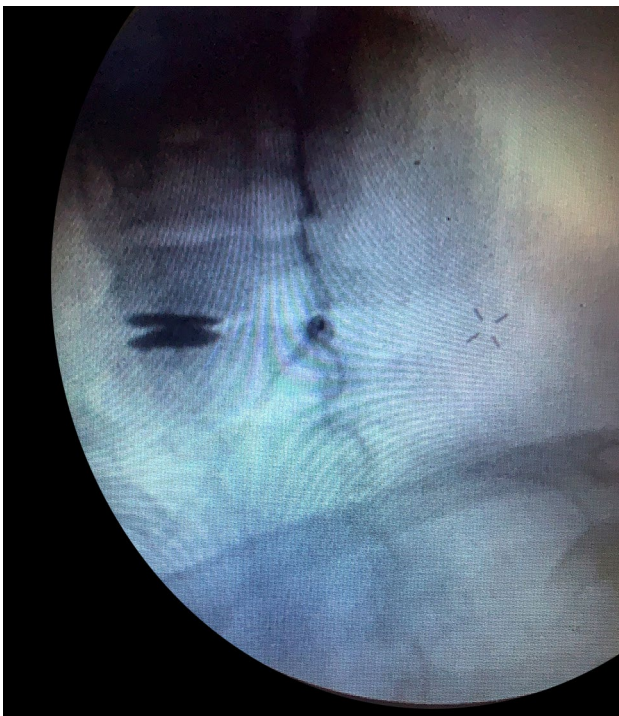## CASE REPORT

A 52-year-old female patient was admitted to our outpatient clinic with complaint of neuropathic pain radiating to her right arm. The patient underwent cervical spinal fusion surgery four years ago and she had a cage at the C7-T1 level, but her pain did not significantly relieved. On physical examination, the spurling test was positive on the right side. Hypoesthesia was detected in C6 and C7 dermatomes, and the upper extremity muscle strength was normal. The deep tendon reflexes were normoactive. Right C7 TESI was planned, since she did not respond to conservative treatment (oral analgesics, exercises, and rehabilitation programs).

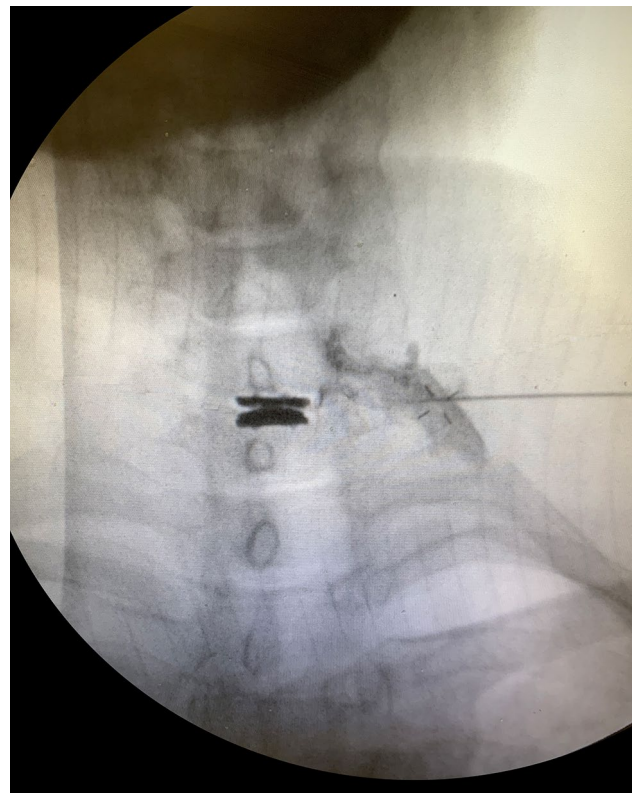
The patient was placed in the supine position, and cutaneous anesthesia was performed with 3 mL of 2% prilocaine using sterile technique. The right C7 foramen was visualized by fluoroscopy. A 90-mm-long 22-gauge spinal Quincke needle was advanced to the right C7 foramen under intermittent fluoroscopic imaging (Figure 1). Contrast material was injected under continued imaging, and anteroposterior imaging revealed that the opaque substance spread along the nerve root (Figure 2). After negative aspiration, a mixture of 1 mL of lidocaine 2%

and 2 mL of dexamethasone were injected, and the procedure was completed.

Subsequently, the patient was asked to resume a sitting position. Within the next minute, she first stated that she could not lift her right arm immediately after the procedure. Meanwhile, she started to feel weakness in her right leg and could not move her leg. In her examination, flaccid paralysis was detected in the right upper and lower extremities, and right-sided hypoesthesia was detected. No deficit was detected in the left-side muscle strength and sensory examination. The patient's deep tendon reflexes were evaluated as normoactive, and pathological reflexes (Hoffman and Babinski signs) were not found. It is well documented that reflexes can be preserved in spinal cord injuries, and pathological reflexes sometimes do not occur.<sup>[4]</sup> In addition, the weak response in the lower extremity to painful stimuli led us to doubt the diagnosis of SCI/ischemia. The patient complained of severe neck and back pain. Her blood pressure was 85/50 mmHg, and the pulse was 70/min. Urgently, 1,000 mL of saline 0.9% (isotonic saline solution) was given intravenously.



**Figure 1.** The spinal needle appears to remain inferior to the C7 foramen and posterior to the ideal location.



**Figure 2.** Contrast medium radiating along the C7 root on anteroposterior imaging. The spinal needle is indicated by an arrow. The arrowheads show the radiopaque wires in the pillow placed under the patient's head.

Cervical magnetic resonance imaging (MRI) and brain diffusion MRI were performed. In addition, vertebral and carotid system computed tomography angiography was carried out. No pathology was detected in the imaging studies. Considering the possibility of malingering, a psychiatry consultation was indicated. The patient was receiving quetiapine 200 mg and duloxetine 60 mg per day for major depressive disorder. The psychiatrist was scheduled for follow-up, as organic pathology could not be excluded.

Pulse methylprednisolone (1 g/intravenous bolus) treatment was applied to the patient with a preliminary diagnosis of SCI. Her blood pressure was followed, systolic blood pressure was balanced at 90 to 110 mmHg, and diastolic blood pressure at 60 to 70 mmHg. Considering that organ perfusion was sufficient, vasopressor agent treatment was not required. At the end of 24 h, the patient completely regained her former muscle strength. Upper and lower extremity muscle strengths were evaluated as 5/5 on examination. Deep tendon reflexes were normoactive, as in the beginning, and no pathological reflexes were found. Spinal diffusion-weighted MRI was performed at 24 h after the procedure, and no diffusion restriction was observed. As a result, the case was diagnosed with a transient ischemic attack of the spinal cord.<sup>[5]</sup>

## DISCUSSION

Numerous complications have been reported in cervical epidural injections and major complications of these injections include infection (abscess/meningitis), epidural hematoma, new neurological deficit due to intramedullary injections, and strokes due to intravascular injections. Therefore, cervical TESI has not yet been approved by the United States Food and Drug Administration (FDA).<sup>[6]</sup> Particulate steroids are insoluble in water and form aggregates. Animal studies have shown that intra-arterial injections cause embolic infarcts by forming aggregates.<sup>[7]</sup> Although particulate steroids were not used in the present case, we believe that this complication occurred by another mechanism.

The blood supply of the spinal cord is quite complex and variable. There are two basic circulatory systems: the segmental arterial system and the superficial arterial system.<sup>[8]</sup> Cervical spinal cord segmental arteries are branches of the vertebral arteries, deep cervical arteries or superior intercostal arteries.<sup>[8,9]</sup> The segmental arteries enter through the intervertebral foramen and form the radicular artery. While the radicular arteries are principally

involved in feeding the nerve root and dura mater, they sometimes directly contribute to the nutrition of the spinal cord. In the latter case, they are called as radiculomedullary artery.<sup>[8]</sup> Some authors have claimed that segmental medullary arteries play a major role in the spinal cord blood supply, and the occlusion of radicular arteries may cause spinal cord infarction.<sup>[10]</sup> Even if the recommended procedure technique for cervical transforaminal injections is performed correctly, there is still a risk of complication due to an excess of anatomical variations.<sup>[10,11]</sup>

The superficial arterial system of the spinal cord consists of the pial plexus and the longitudinal artery formed by one anterior and two posterior spinal arteries.<sup>[8]</sup> The anterior spinal artery is formed at the level of the foramen magnum by the fusion of branches separated from both vertebral arteries and extend along the anterior sulcus of the spinal cord to the conus medullaris.<sup>[8]</sup> Due to its long course, the anterior spinal artery receives blood supply through segmental medullary arteries and radiculomedullary arteries.<sup>[8,10]</sup> Furthermore, the anterior spinal artery can perform multiple anastomoses and even duplication.<sup>[8]</sup> In such cases, the supply of the spinal cord in those segments can be provided by the double artery. Perhaps, this can be a possible explanation for why the case had unilateral involvement rather than quadriplegia.

The pial plexus, which connects the posterior spinal arteries and the anterior spinal artery, is another system that contributes to the spinal cord blood supply and nourishes the periphery of the spinal cord.<sup>[8]</sup> Although surgery is not an absolute contraindication for TESI, previous spinal surgery is often cited as a risk factor, since it increases vascular anastomoses in the relevant region. Unfortunately, we cannot predict these undesirable effects of surgery. In the present case, the possibility of an anastomosis between peripheral arteries and these structures, which also branch towards the central spinal cord, may be another possible source of ischemia.

The main cause of SCI due to TESI has been thought to be embolism caused by particulate steroids.<sup>[3]</sup> In our case, we attempted to avoid this risk by using dexamethasone, a particle-free steroid. Some authors have suggested that needle-induced vasospasm may be another potential cause of the etiology of SCI.<sup>[12]</sup> In addition, local anesthetics or steroids may also cause vasospasm.<sup>[13]</sup> It is known that blood supply increases with the formation of new vessels, and many anastomoses occur in patients undergoing surgery. Despite that, it is unpredictable to

identify the number and localization of anastomoses formed after surgery. Spinal angiography could not be performed due to hospital facilities in the present case and, unfortunately, we were unable to demonstrate anastomoses and their blood supply to the spinal cord.

Although their course may vary, radicular arteries usually enter from the inferior part of the intervertebral foramen below the level of origin of the spinal nerve.<sup>[10]</sup> In the present case, the needle was positioned in this section and was slightly posterior to the foramen. Huntton<sup>[13]</sup> reported that the radicular arteries branching from the deep cervical arteries mostly entered the foramen at the C6-C8 level. In addition, two cases of intra-arterial injection were reported during cervical C6 and C7 TESI procedures.<sup>[11,12]</sup> These are also compatible with our case.

Furman et al.<sup>[14]</sup> found that the incidence of intravascular injections was 19.4% in cervical transforaminal injections, and more than half of them had negative aspiration. Baker et al.<sup>[11]</sup> also reported that small vascular leaks could be detected during DSA, thereby preventing a possible cause of SCI. Compared to real-time fluoroscopy, intermittent fluoroscopy may miss some of those vascular injections. This also increases the risk of SCI due to epidural injections. The present case confirms that the negative aspiration test and real-time fluoroscopy (continue acquisition) are not completely reliable. In this context, we agree that DSA should be used to avoid the risk of complications.

Other potential mechanisms in the development of SCI due to cervical TESI include intraparenchymal injection, epidural abscess, and epidural hematoma. Of note, SCIs secondary to space-occupying lesions such as hematomas and abscesses are more reversible than infarcts.<sup>[15]</sup> As expected, these lesions develop over a longer period of time. In our case, we ruled out possible causes such as abscess and hematoma, since motor weakness and paresthesia developed immediately after the injection. In addition, we confirmed this exclusion with cervical MRI.

Patients may present with signs of SCI such as hypotension, respiratory distress (respiratory distress), chest and back pain, paresthesia, weakness, and fever.<sup>[2]</sup> In our case, the chief complaints of the patient started within minutes following the procedure. There were signs of hypotension, severe back pain, paresthesia, and weakness.

In conclusion, cervical TESI are among the interventional pain management procedures with a high risk of complications. The high variability of cervical spinal cord blood supply, particularly in patients undergoing surgery, and the presence of a rich vascular collateral network make the results of the procedure somewhat unpredictable. Therefore, we need to be more selective and very careful in choosing patients for cervical TESI.

**Patient Consent for Publication:** A written informed consent was obtained from patient.

**Data Sharing Statement:** The data that support the findings of this study are available from the corresponding author upon reasonable request.

**Author Contributions:** All authors contributed equally to the article.

**Conflict of Interest:** The authors declared no conflicts of interest with respect to the authorship and/or publication of this article.

**Funding:** The authors received no financial support for the research and/or authorship of this article.

## REFERENCES

1. Benny B, Azari P, Briones D. Complications of cervical transforaminal epidural steroid injections. *Am J Phys Med Rehabil* 2010;89:601-7. doi: 10.1097/PHM.0b013e3181e2d07c.
2. Schreiber AL, McDonald BP, Kia F, Fried GW. Cervical epidural steroid injections and spinal cord injuries. *Spine J* 2016;16:1163-6. doi: 10.1016/j.spinee.2015.08.068.
3. Benny B, Azari P, Briones D. Complications of cervical transforaminal epidural steroid injections. *Am J Phys Med Rehabil* 2010;89:601-7. doi: 10.1097/PHM.0b013e3181e2d07c.
4. Zalewski NL, Rabinstein AA, Krecke KN, Brown RD Jr, Wijdicks EFM, Weinschenker BG, et al. Characteristics of spontaneous spinal cord infarction and proposed diagnostic criteria. *JAMA Neurol* 2019;76:56-63. doi: 10.1001/jamaneurol.2018.2734.
5. Panuganti KK, Tadi P, Lui F. Transient Ischemic Attack. In: *StatPearls*. Treasure Island (FL): StatPearls Publishing LLC.; 2021.
6. Epstein NE. Major risks and complications of cervical epidural steroid injections: An updated review. *Surg Neurol Int* 2018;9:86. doi: 10.4103/sni.sni\_85\_18.
7. Schneider BJ, Maybin S, Sturos E. Safety and complications of cervical epidural steroid injections. *Phys Med Rehabil Clin N Am* 2018;29:155-69. doi: 10.1016/j.pmr.2017.08.012.
8. Santillan A, Nacarino V, Greenberg E, Riina HA, Gobin YP, Patsalides A. Vascular anatomy of the spinal cord. *J Neurointerv Surg* 2012;4:67-74. doi: 10.1136/neurintsurg-2011-010018.
9. Dommissie GF. The blood supply of the spinal cord. A critical vascular zone in spinal surgery. *J Bone Joint Surg [Br]* 1974;56:225-35.



10. Hoeft MA, Rathmell JP, Monsey RD, Fonda BJ. Cervical transforaminal injection and the radicular artery: Variation in anatomical location within the cervical intervertebral foramina. *Reg Anesth Pain Med* 2006;31:270-4. doi: 10.1016/j.rapm.2005.12.005.
11. Baker R, Dreyfuss P, Mercer S, Bogduk N. Cervical transforaminal injection of corticosteroids into a radicular artery: A possible mechanism for spinal cord injury. *Pain* 2003;103:211-5. doi: 10.1016/s0304-3959(02)00343-3.
12. Brouwers PJAM, Kottink EJBL, Simon MAM, Prevo RL. A cervical anterior spinal artery syndrome after diagnostic blockade of the right C6-nerve root. *Pain* 2001;91:397-9. doi: 10.1016/S0304-3959(00)00437-1.
13. Huntoon MA. Anatomy of the cervical intervertebral foramina: Vulnerable arteries and ischemic neurologic injuries after transforaminal epidural injections. *Pain* 2005;117:104-11. doi: 10.1016/j.pain.2005.05.030.
14. Furman MB, Giovanniello MT, O'Brien EM. Incidence of intravascular penetration in transforaminal cervical epidural steroid injections. *Spine (Phila Pa 1976)* 2003;28:21-5. doi: 10.1097/00007632-200301010-00007.
15. Bloodworth DM, Perez-Toro MR, Nouri KH. Neurological deficits after epidural steroid injection: Time course, differential diagnoses, management, and prognosis suggested by review of case reports. *Pain Medicine* 2008;9 Suppl\_1:S41-57. doi: 10.1111/j.1526-4637.2008.00439.x.