

# Hourglass-like constrictions of the radial nerve in the neuralgic amyotrophy: A case report

İsmail Koç<sup>1</sup>, Betül Özenç<sup>2</sup>, Bülent Kurt<sup>3</sup>, Ersin Erdoğan<sup>4</sup>, Zeki Odabaşı<sup>5</sup>

<sup>1</sup>Department of Neurology, Dışkapı Yıldırım Beyazıt Training and Research Hospital, Ankara, Türkiye

<sup>2</sup>Department of Neurology, Gülhane Training and Research Hospital, Ankara, Türkiye

<sup>3</sup>Department of Pathology, Private Clinic, Ankara, Türkiye

<sup>4</sup>Department of Neurosurgery, Private Clinic, Ankara, Türkiye

<sup>5</sup>Department of Neurology, University of Health Sciences, Gülhane Medical School, Ankara, Türkiye

Received: August 18, 2022 Accepted: March 08, 2023 Published online: May 05, 2023

## ABSTRACT

Neuralgic amyotrophy (NA) is a peripheral nerve disorder that has a classical presentation as motor deficit after severe pain, but it is still overlooked or misdiagnosed. Formerly, the diagnosis was based on the clinical picture and electrophysiology; however, sophisticated imaging and surgical modalities showed structural abnormalities such as hourglass-like constrictions of the nerves. In this article, we present a case presenting with drop hand mimicking radial nerve entrapment. The patient was diagnosed with NA and surgery revealed hourglass-like constrictions. The clinical findings were improved after neurolysis and physical therapy. In conclusion, hourglass-like constrictions can be prognostic factors of NA and should be searched carefully.

**Keywords:** Hourglass-like constriction, neuralgic amyotrophy, neurolysis, neurolysis, neurolysis, radial nerve palsy.

Neuralgic amyotrophy (NA), also known as Parsonage-Turner syndrome or brachial plexus neuritis, typically presents with sudden-onset upper extremity pain, followed by multifocal paresis and muscle atrophy.<sup>[1]</sup> Its incidence was previously estimated as 2 to 3/100,000 per year; however, it is estimated as 1/1,000 currently.<sup>[2]</sup>

Hourglass-like constrictions (HLCs) are characterized by narrowing in the nerve fascicles which were first seen in the mononeuritis many years ago;<sup>[3,4]</sup> however, HLCs have been reported in NA cases increasingly day by day. These constrictions have changed the treatment modality from conservative way (i.e., corticosteroids) to surgery (i.e., neurolysis, neurolysis, or even neuron grafting).<sup>[1]</sup>

In this article, we report a case of NA presenting with drop hand which was misdiagnosed as radial nerve entrapment.

## CASE REPORT

A 35-year-old male airline pilot with an unremarkable medical history complained of difficulty in the extension of his left hand and fingers shortly after sudden pain in his arm. He was diagnosed with radial nerve entrapment neuropathy, and non-steroidal anti-inflammatory drugs were initiated in the acute period to alleviate the pain. He, then, attended to a physical therapy and rehabilitation program. However, his complaint persisted and he was referred to decompression surgery. The first

**Corresponding author:** İsmail Koç, MD, Dışkapı Yıldırım Beyazıt Eğitim ve Araştırma Hastanesi, Nöroloji Kliniği, 06110 Altındağ, Ankara, Türkiye.

E-mail: ismailkoc.tip@gmail.com

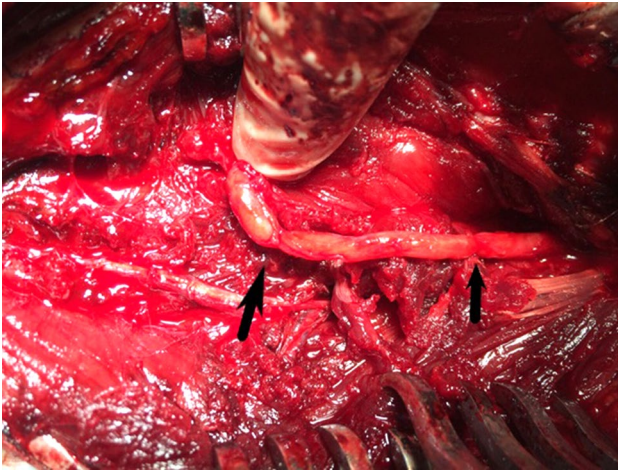
Cite this article as:

Koç İ, Özenç B, Kurt B, Ersin E, Odabaşı Z. Hourglass-like constrictions of the radial nerve in the neuralgic amyotrophy: A case report. Turk J Phys Med Rehab 2023;69(x):i-iii. doi: 10.5606/tftrd.2023.11554

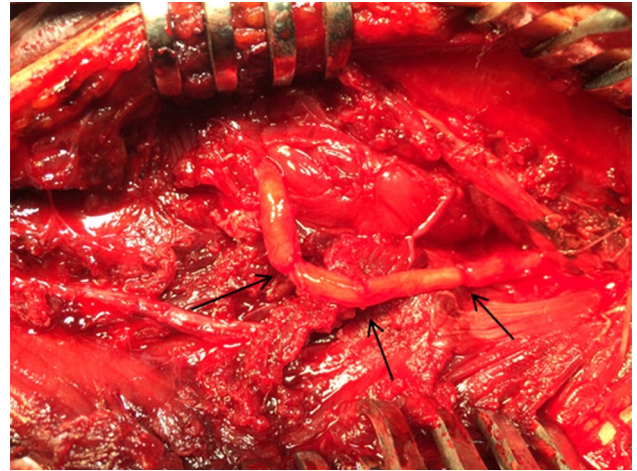
©2023 All right reserved by the Turkish Society of Physical Medicine and Rehabilitation

This is an open access article under the terms of the Creative Commons Attribution-NonCommercial License, which permits use, distribution and reproduction in any medium, provided the original work is properly cited and is not used for commercial purposes (<http://creativecommons.org/licenses/by-nc/4.0/>).





**Figure 1.** Hourglass-like constrictions of the main trunk of the radial nerve were treated with neurorrhaphy.



**Figure 2.** Three hourglass-like constrictions on the main trunk of the radial nerve are seen.

decompression surgery on the radial nerve at the spiral groove was performed six weeks after the symptoms began. Two months after the initial surgery, he was admitted to our center. We considered that the localization was wrong, as the complaints of the patient and electroneuromyography (EMG) results were incompatible. In our center, EMG showed a total lesion of the radial nerve proximal to the elbow and distal to the spiral groove, in which the sensory branch was spared. He was scheduled for surgery for exploration, and the second surgery was performed on a place between the spiral groove and proximal elbow level. During surgery, three severe constrictions were revealed in the main trunk of the radial nerve a few centimeters proximal to the lateral epicondyle (Figures 1 and 2). The constricted portion was resected, and neurorrhaphy was performed. In pathological examination, serial sections showed small proliferating nerve fascicles surrounded by collagen. Ten months later, poor recovery was achieved, and repeated EMG showed regeneration and reinnervation potentials in radial nerve-innervated forearm muscles, including the brachioradialis. The patient was followed with the diagnosis of NA, instead of radial neuropathy. After two years, his complaints were completely resolved and he returned to his job.

## DISCUSSION

Neuralgic amyotrophy has been recognized better than earlier, and the diagnosis of NA has increased with the contribution of improved radiological techniques and surgical methods.<sup>[1]</sup> Despite this, the

exact pathophysiological mechanism of NA has not been elucidated, yet. Autoimmune processes have been mostly blamed, due to inflammation in the selected nerves.<sup>[3,5]</sup>

Recently, HLCs, one of the findings of mononeuropathies such as anterior or posterior interosseous nerve syndromes, have been reported in cases of NA.<sup>[5,6]</sup> The association of HLCs with NA and its prognostic value have been proven, and the surgical approach can be an alternative treatment method for NA patients with HLCs.<sup>[1]</sup> Nagano et al.<sup>[4]</sup> claimed that swelling and adhesion of nerve fascicles could develop secondary to an inflammatory process. They also advocated that limb movement and mechanical traumas could play a role in forming HLCs. Swelled nerve portion can be less flexible, and repeated limb motion can induce kinking, torsion and, consequently constrictions.<sup>[1,4]</sup> The present case was admitted to our clinic before the novel coronavirus disease 2019 (COVID-19) pandemic, and there was no infection or vaccination in his history.

Previously, only corticosteroids and physical therapies were used in the treatment; however, a few studies in the literature have shown the benefit of neurolysis, neurorrhaphy or nerve grafting for the cases of NA, particularly for those with HLCs.<sup>[3]</sup> Although the optimal time for surgery is not clear, it is considered that the nerve can recover spontaneously within three months.<sup>[1,3]</sup> When clinical or electrophysiological findings are not improved within the first three months, the patients with NA should undergo magnetic resonance neurography

(MRN) or high-resolution ultrasonography (USG), and they should be referred to surgery, if HLCs are seen in radiological imaging.<sup>[1,5]</sup>

Although NA was considered to be a self-limiting condition formerly, recent studies have shown that spontaneous prognosis of NA is not favorable. The majority of patients have residual pain or paresis in the course of months to years, even if they receive conservative treatment.<sup>[1,5,6]</sup> On the other hand, studies have demonstrated that surgical interventions in NA are significantly beneficial.<sup>[3]</sup> Our patient recovered completely after a successful neurolysis and physiotherapy; therefore, early surgical intervention should be performed to avoid irreversible damage. Our patient did not undergo MRN or USG; however, undoubtedly radiological imaging has a vital role to show HLCs and rule out possible pathologies such as a tumor. That is why cooperation among surgeon, radiologists, and neurologists is of utmost importance in cases of NA. Also, a well-planned physical therapy program by the physiatrist should be a part of the NA treatment.

In conclusion, the diagnosis and treatment of NA can be challenging, even if the patient has a typical clinical picture. Neuralgic amyotrophy should be identified as possible as early and surgical intervention is necessary for full recovery, if NA presents with HLCs.

**Patient Consent for Publication:** A written informed consent was obtained from patient.

**Data Sharing Statement:** The data that support the findings of this study are available from the corresponding author upon reasonable request.

**Author Contributions:** Idea/concept: I.K., B.K., Z.O.; Design, data collection and/or processing: I.K., B.O., E.E., Z.O.; Control/supervision, critical review: Z.O.; Analysis and/or interpretation: B.O., Z.O.; Literature review: I.K., B.O., B.K., E.E.; Writing the article: I.K., Z.O.; References and fundings, materials: B.K., E.E., Z.O.

**Conflict of Interest:** The authors declared no conflicts of interest with respect to the authorship and/or publication of this article.

**Funding:** The authors received no financial support for the research and/or authorship of this article.

## REFERENCES

1. Gstoettner C, Mayer JA, Rassam S, Hruby LA, Salminger S, Sturma A, et al. Neuralgic amyotrophy: A paradigm shift in diagnosis and treatment. *J Neurol Neurosurg Psychiatry* 2020;91:879-88. doi: 10.1136/jnnp-2020-323164.
2. IJspeert J, Janssen RMJ, van Alfen N. Neuralgic amyotrophy. *Curr Opin Neurol* 2021;34:605-12. doi: 10.1097/WCO.0000000000000968.
3. Pan Y, Wang S, Zheng D, Tian W, Tian G, Ho PC, et al. Hourglass-like constrictions of peripheral nerve in the upper extremity: A clinical review and pathological study. *Neurosurgery* 2014;75:10-22. doi: 10.1227/NEU.0000000000000350.
4. Nagano A, Shibata K, Tokimura H, Yamamoto S, Tajiri Y. Spontaneous anterior interosseous nerve palsy with hourglass-like fascicular constriction within the main trunk of the median nerve. *J Hand Surg Am* 1996;21:266-70. doi: 10.1016/S0363-5023(96)80114-6.
5. Krishnan KR, Sneag DB, Feinberg JH, Nwawka OK, Lee SK, Arányi Z, et al. Outcomes of microneurolysis of hourglass constrictions in chronic neuralgic amyotrophy. *J Hand Surg Am* 2021;46:43-53. doi: 10.1016/j.jhsa.2020.07.015.
6. Nakagawa Y, Hirata H. Hourglass-like constriction of the brachial plexus in the posterior cord: A case report. *Neurosurgery* 2018;82:E1-5. doi: 10.1093/neuros/nyx171.