

Ultrasound-guided lateral branch radiofrequency ablation for sacroiliac joint pain

Serdar Kokar¹, Özlem Mercan², Kenan Akgün¹

¹Department of Physical Medicine and Rehabilitation, Pain Management Section, Istanbul University - Cerrahpaşa, Faculty of Medicine, Istanbul, Türkiye

²Department of Neurology, Pain Management Section, Istanbul University - Cerrahpaşa, Faculty of Medicine, Istanbul, Türkiye

Received: March 07, 2021 Accepted: July 08, 2021 Published online: August 25, 2022

ABSTRACT

Sacroiliac joint (SIJ) pain is one of the leading causes of mechanical low back pain. Treatment includes conservative methods, surgery, and radiofrequency thermocoagulation (RFTC) as a novel therapeutic approach. Herein, we present a 71-year-old female patient who was first admitted to the outpatient clinic about four years ago. The medical history and physical examination findings were compatible with SIJ pain. After unresponsiveness to previous treatments, the patient successfully underwent ultrasound-guided RFTC using the lateral crest technique. This case report demonstrates, for the first time, the long-term efficacy of ultrasound-guided RFTC using the lateral crest technique in the management of SIJ pain.

Keywords: Low back pain, radiofrequency ablation, sacroiliac joint, ultrasonography.

The sacroiliac joints (SIJs) connect the sacrum to the pelvis and transfer the load effectively between the spine and lower extremities.^[1] Pathologies of the SIJs are the leading causes of mechanical low back pain. In addition to major injuries, tumors, infectious and inflammatory diseases, pain is usually caused by axial loading and rotation.^[2] Leg length discrepancy, previous lumbar surgery, transitional vertebra, scoliosis, gait abnormalities, and pregnancy increase the load on the SIJs, resulting in pain.^[2] Immunohistochemical studies have shown the presence of nociceptors in the joint capsule, ligaments, and throughout the subchondral bone.^[3,4] Therefore, the origin of the pain may be one of these structures. From this point of view, it can be defined as SIJ pain or SIJ complex pain.^[5] In this case report, the term SIJ pain was used.

Currently, a variety of methods and criteria are used in the diagnosis of SIJ pain, and the prevalence of SIJ pain varies in the literature.^[2,6,7]

Conservative treatment of SIJ pain includes nonsteroidal anti-inflammatory drugs, physical activity modifications, stretching and strengthening exercises, joint manipulation, and physical therapy. In addition to these methods, therapeutic SIJ injections can be applied with local anesthetics or steroids.^[8] Surgery is the last resort, performed when patients remain unresponsive to all these treatments.^[9] Furthermore, radiofrequency thermocoagulation (RFTC) can be administered to the lateral branches of the posterior sacral rami before surgery.^[10] This method is relatively new and has been increasingly used in recent years; however, it requires fluoroscopic guidance. Of note, in a systematic review, the efficacy of RFTC under the guidance of fluoroscopy was found to be limited.^[5] This can be attributed to poor visualization of the posterior sacral foramen.^[11] In this context, ultrasound (US) imaging has major advantages, as it is easily accessible and

Corresponding author: Serdar Kokar, MD. İstanbul Üniversitesi - Cerrahpaşa, Tıp Fakültesi, Fiziksel Tıp ve Rehabilitasyon Anabilim Dalı, Ağrı Tedavisi Bilim Dalı, 34098 Fatih, İstanbul, Türkiye. e-mail: srdrkkr@hotmail.com

Cite this article as:

Kokar S, Mercan Ö, Akgün K. Ultrasound-guided lateral branch radiofrequency ablation for sacroiliac joint pain. Turk J Phys Med Rehab 2022;68(3):430-434.

©2022 All right reserved by the Turkish Society of Physical Medicine and Rehabilitation

This is an open access article under the terms of the Creative Commons Attribution-NonCommercial License, which permits use, distribution and reproduction in any medium, provided the original work is properly cited and is not used for commercial purposes (<http://creativecommons.org/licenses/by-nc/4.0/>).



does not use ionizing radiation. In this article, we report the first case of SIJ pain treated with US-guided RFTC to the lateral sacral branches.

CASE REPORT

A 71-year-old female patient was first admitted to the physical medicine and rehabilitation outpatient clinic in September 2016 and was taken under follow-up. At the time of their first admission, the patient had low back pain for about 10 years and was operated on for lumbar disc herniation two years ago. The patient's medical history and physical examination findings were compatible with SIJ pain. The SIJ provocation and mobility test results were positive.^[7] These tests are frequently used by physicians to assess sacroiliac tenderness and include Gaenslen's and Mennell's tests, thigh thrust, flexion, abduction, and external rotation (FABER) test, and sacroiliac compression and distraction tests.^[7] There was tenderness over the right SIJ with compression; however, the straight leg raise test and femoral nerve stretch test yielded negative results. No sacroiliitis or fracture was detected in the sacroiliac magnetic resonance imaging. Therefore, it was considered that the pain might be related to sacroiliac joint dysfunction. For diagnostic purposes, 4 mL of 2% lidocaine was injected into and around the SIJ under the guidance of US. According to the Numeric Rating Scale (NRS), pain severity was 10/10 before the procedure but decreased to 1/10 at the postoperative first hour. The SIJ provocation tests were all negative. The patient was given an exercise program and discharged with recommendations.

The effect of diagnostic lidocaine injection sustained for about one month. Afterward, she received a total of four injections with at least three-month intervals between two injections. All injections were applied under the guidance of US, and 1 mL betamethasone was added to the latter four injections. 0.5 mL of betamethasone and 1.5 mL of 2% lidocaine was injected intra-articularly, and the rest 0.5 mL of betamethasone and 1.5 mL of 2% lidocaine was applied extra-articularly, particularly to the other sources of pain and ligaments along the joint.^[12] Following the first injection with betamethasone, the patient remained pain-free for three months. However, the effectiveness of betamethasone in preventing pain gradually decreased to one month. During follow-up in June 2019, the patient was recommended RFTC therapy to achieve a longer duration of pain-free status, and RFTC was applied under the guidance of US to the lateral branches of the posterior sacral rami. According to the NRS, pain severity was 10/10 before the procedure. On physical examination, Gaenslen's and Mennell's tests, SIJ compression and distraction, thigh thrust test, and Fortin finger test results were all positive. Low back pain was not provoked with lumbar testing, and no motor deficit was detected.

The patient was placed in the prone position and monitored. The right SIJ area was cleaned with povidone-iodine three times. The procedure was performed by a pain management specialist with more than 15 years of experience in US-guided interventional procedures. A low-frequency (2 to 5 MHz) curvilinear transducer (LOGIQ P5; GE Healthcare, Buckinghamshire, UK) was used.

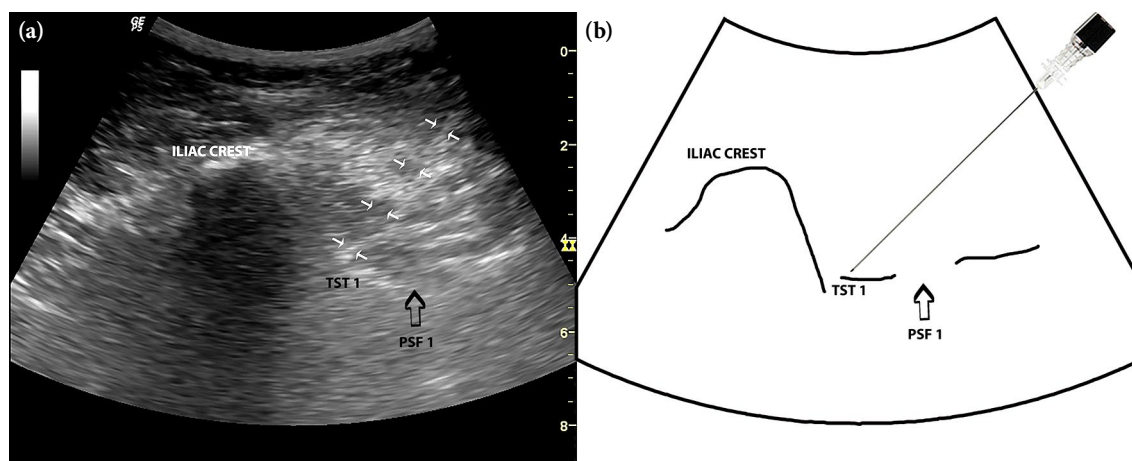


Figure 1. (a), An US image of the 21-gauge radiofrequency cannula advanced to the first TST target using in-plane approach (arrows). (b) Bony landmarks are highlighted in the schematic drawing.

US: Ultrasound; TST 1: First transverse sacral tubercle; PSF 1: First posterior sacral foramen.

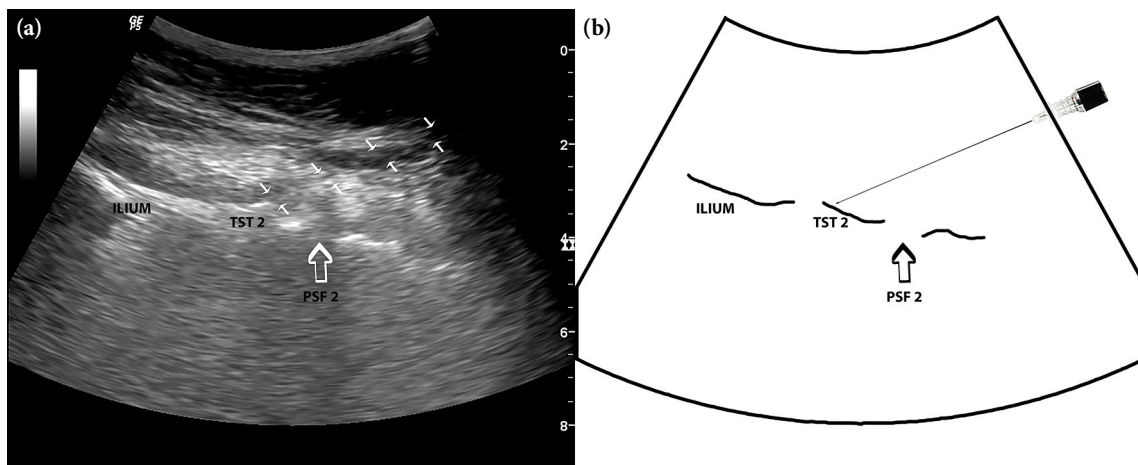


Figure 2. (a), An US image of the 21-gauge radiofrequency cannula advanced to the second TST target using in-plane approach (arrows). (b) Bony landmarks are highlighted in the schematic drawing.

US: Ultrasound; TST 2: Second transverse sacral tubercle; PSF 2: Second posterior sacral foramen.

The treatment method was based on the lateral crest technique as previously described by Roberts et al.^[11] Accordingly, the bony landmarks used to identify the lateral sacral crest where the posterior sacral network extends were the posterior sacral foramina and the first to third transverse sacral tubercles (TSTs). For this purpose, the fourth posterior sacral foramen at the level of the sacral cornua was visualized in the transverse plane. The probe was then slid upward, and other sacral foramina and TSTs at the corresponding levels were visualized. The first, second, and third TSTs were targeted, and the radiofrequency cannulas (21-gauge) were advanced to

these targets using in-plane (Figure 1a and b), in-plane (Figure 2a and b), and out-of-plane (Figure 3a and b) approaches, respectively. Bone contact was ensured, and a radiofrequency electrode was placed. A sensory stimulus was administered at 50 Hz, and the patient was told to inform the operator in case of tingling, electric shock-like sensation, or numbness. For each level, paresthesia was achieved below 0.6 V. Subsequently, a motor stimulus was applied at 2 Hz through the paresthesia points, and the absence of muscle contraction in the lower extremities was ensured. Before thermocoagulation, a small amount (0.5 mL) of 2% lidocaine was injected to avoid the spread of the

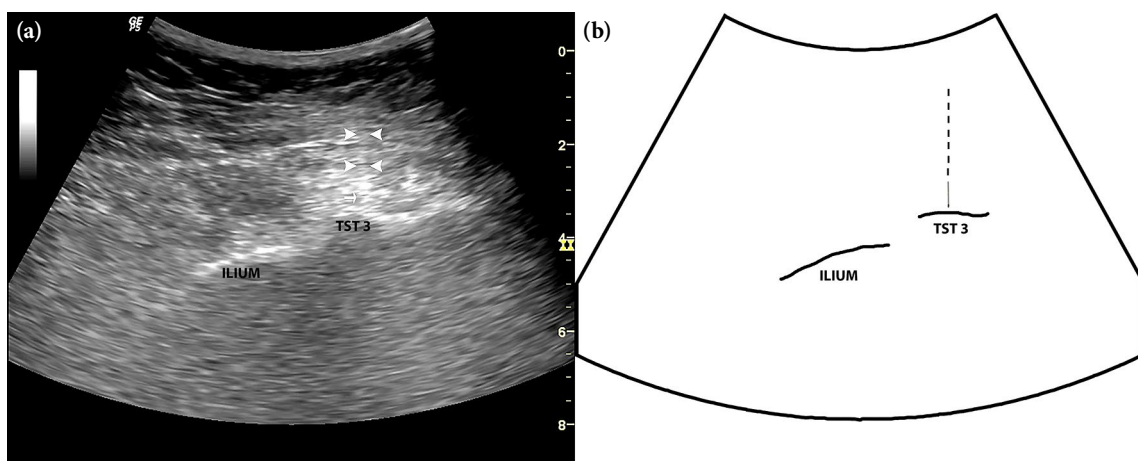


Figure 3. (a), An US image of the 21-gauge radiofrequency cannula advanced to the third TST target using out-of-plane approach. Arrow heads indicate the needle pathway. The arrow shows the needle tip. (b) Bony landmarks are highlighted in the schematic drawing.

US: Ultrasound; TST 3: Third transverse sacral tubercle.

injectant to the other levels. Afterward, radiofrequency ablation was applied at 80° for 90 min. Following thermocoagulation, 0.5 mL of betamethasone was injected into each level. At the postoperative first hour, the NRS score was 2/10, and SIJ provocation test results were all negative. No intra-procedural complication was observed. The patient was advised to lose weight and exercise before discharge.

The patient was scheduled for follow-up visits at one week, 1, 3, 6, 9, and 12 months. In these follow-ups, the NRS scores were 2/10, 2/10, 2/10, 2/10, 5/10, and 10/10, respectively. Although all provocation tests for SIJ were negative, sensitivity was detected at 9 and 12 months based on the Fortin finger test.

DISCUSSION

The present case report is the first to demonstrate the long-term efficacy of US-guided RFTC in the management of SIJ pain. Before the procedure, pain severity was 10/10 on the NRS. During the six months following the procedure, an 80% decrease was achieved in pain severity. Considering that the case was refractory to other pain management modalities, this outcome is noteworthy. However, the RFTC should not be the first-line and only treatment option in the management of SIJ pain. Foremost, lifestyle changes such as weight loss, exercise, and physical activity modifications should be recommended, and these should be considered the main components of the management plan.

The SIJs are innervated by not only S1-S3 but also L5 and S4 dorsal rami and obturator and superior gluteal nerve branches.^[5] This can explain persistent pain in the case, which did not completely resolve (2/10 NRS). Nonetheless, the application of RFTC to these branches is another subject to be addressed. It is not always possible to interfere with the central sensitization by blocking the peripheral input in patients with chronic SIJ pain. Therefore, no modification was made in the initial treatment (gabapentin 600 mg three times a day) in the case.

The pain was not associated with lumbar strain based on physical examination findings in the present case, although diagnostic blocks were not performed to rule out this possibility. Given the fact that the majority of patients with chronic low back pain have multiple diagnoses (≥ 2), this can be considered a limitation.^[13] Furthermore, one of the main disadvantages of fluoroscopy-guided RFTC to the sacral lateral branches is that visualization of the

posterior sacral foramina can be challenging, leading to the misplacement of the needle to the foramen or its adjacent spaces. This results in sacral nerve ablation and incontinence, increased pain severity, and lower extremity weakness.^[11] Conversely, needle placement by the US-guided lateral crest technique, utilized in our case, is sufficiently lateral to the posterior sacral foramina to avoid misplacement within or adjacent to the foramina and adequately medial to reach the posterior sacral network.^[11] Visualization of the TSTs, one of the bony landmarks, allows depth measurement and location optimization.

In conclusion, US can be considered the first-line imaging modality in RFTC to the sacral lateral branches in the management of SIJ pain as it allows easy visualization of the bony landmarks, does not use ionizing radiation, and is easily accessible and relatively cost-effective. However, further randomized-controlled clinical studies are needed to achieve more robust evidence supporting this modality in the management of SIJ pain.

Patient Consent for Publication: A written informed consent was obtained from the patient for all the diagnostic and therapeutic procedures and the publication of this article.

Data Sharing Statement: The data that support the findings of this study are available from the corresponding author upon reasonable request.

Author Contributions: Acquired the data and drafted the article: S.K., Ö.M.; Analyzed and interpreted the data, and revised the article: K.A.; All authors have seen and approved the final version of the manuscript.

Conflict of Interest: The authors declared no conflicts of interest with respect to the authorship and/or publication of this article.

Funding: The authors received no financial support for the research and/or authorship of this article.

REFERENCES

1. Foley BS, Buschbacher RM. Sacroiliac joint pain: Anatomy, biomechanics, diagnosis, and treatment. *Am J Phys Med Rehabil* 2006;85:997-1006.
2. Cohen SP, Chen Y, Neufeld NJ. Sacroiliac joint pain: A comprehensive review of epidemiology, diagnosis and treatment. *Expert Rev Neurother* 2013;13:99-116.
3. Szadek KM, Hoogland PV, Zuurmond WW, de Lange JJ, Perez RS. Nociceptive nerve fibers in the sacroiliac joint in humans. *Reg Anesth Pain Med* 2008;33:36-43.
4. Szadek KM, Hoogland PV, Zuurmond WW, De Lange JJ, Perez RS. Possible nociceptive structures in the sacroiliac joint cartilage: An immunohistochemical study. *Clin Anat* 2010;23:192-8.

5. King W, Ahmed SU, Baisden J, Patel N, Kennedy DJ, Duszynski B, et al. Diagnosis and treatment of posterior sacroiliac complex pain: A systematic review with comprehensive analysis of the published data. *Pain Med* 2015;16:257-65.
6. Schwarzer AC, Aprill CN, Bogduk N. The sacroiliac joint in chronic low back pain. *Spine (Phila Pa 1976)* 1995;20:31-7.
7. Ozgocmen S, Bozgeyik Z, Kalcik M, Yildirim A. The value of sacroiliac pain provocation tests in early active sacroiliitis. *Clin Rheumatol* 2008;27:1275-82.
8. Rashbaum RF, Ohnmeiss DD, Lindley EM, Kitchel SH, Patel VV. Sacroiliac joint pain and its treatment. *Clin Spine Surg* 2016;29:42-8.
9. Cohen SP. Sacroiliac joint pain: A comprehensive review of anatomy, diagnosis, and treatment. *Anesth Analg* 2005;101:1440-53.
10. Robinson TJ, Roberts SL, Burnham RS, Loh E, Agur AM. Sacro-iliac joint sensory block and radiofrequency ablation: Assessment of bony landmarks relevant for image-guided procedures. *Biomed Res Int* 2016;2016:1432074.
11. Roberts SL, Burnham RS, Agur AM, Loh EY. A cadaveric study evaluating the feasibility of an ultrasound-guided diagnostic block and radiofrequency ablation technique for sacroiliac joint pain. *Reg Anesth Pain Med* 2017;42:69-74.
12. Yin W, Willard F, Carreiro J, Dreyfuss P. Sensory stimulation-guided sacroiliac joint radiofrequency neurotomy: Technique based on neuroanatomy of the dorsal sacral plexus. *Spine (Phila Pa 1976)* 2003;28:2419-25.
13. Cohen SP, Abdi S. Lateral branch blocks as a treatment for sacroiliac joint pain: A pilot study. *Reg Anesth Pain Med* 2003;28:113-9.