



# The effectiveness of prolotherapy on failed rotator cuff repair surgery

Serkan Akpancar<sup>1</sup>, Aydan Örsçelik<sup>2</sup>, Mehmet Murat Seven<sup>3</sup>, Kenan Koca<sup>4</sup>

<sup>1</sup>Department of Orthopedics and Traumatology, Tokat State Hospital, Tokat, Turkey

<sup>2</sup>Department of Sports Medicine, Gülhane Training and Research Hospital, Ankara, Turkey

<sup>3</sup>Special Forces Command, Sports Medicine, Ankara, Turkey

<sup>4</sup>Department of Orthopedics and Traumatology, Gülhane Training and Research Hospital, Ankara, Turkey

Received: June 03, 2018 Accepted: November 30, 2018 Published online: February 06, 2019

## ABSTRACT

**Objectives:** The aim of the present study was to investigate the effectiveness of prolotherapy injections in the treatment of failed rotator cuff repair surgery.

**Patients and methods:** Between May 2014 and March 2016, a total of 15 patients (5 males, 10 females; mean age 49.4±10.7 years; range, 33 to 71 years) with failed rotator cuff repair surgery who had at least six months of complaints and were refractory to at least of three months of conservative methods were included. Ultrasound-guided prolotherapy injections were performed under aseptic conditions, and the patients were instructed to carry out a home-based exercise program. Clinical assessment of shoulder function was performed using a visual analog scale (VAS) for pain, Shoulder Pain and Disability Index (SPADI), Western Ontario Rotator Cuff (WORC) Index, patient satisfaction and shoulder range of motion. All patients were examined at baseline, at Week 3, 6, and 12 and at the final follow-up visit.

**Results:** The intra-group comparison showed that the patients achieved significant improvements at all time points, compared to baseline as measured by VAS, SPADI, WORC index, and shoulder range of motion ( $p<0.001$ ). Twelve patients (80%) reported excellent or good outcomes.

**Conclusion:** Our study results show that prolotherapy is effective in the treatment of patients with failed rotator cuff repair surgery with significant improvements in the shoulder functions and pain relief.

**Keywords:** Arthroscopy, injection, physiotherapy, rotator cuff injury, shoulder pain, stiffness.

Shoulder arthroscopy has become the gold standard for most shoulder pathologies, owing to the need for smaller incisions, less trauma, and improved postoperative patient comfort.<sup>[1]</sup> Despite recent developments and increased experience in arthroscopy, postoperative stiffness, however, still remains nightmare for clinicians. It is one of the most frequent postoperative complications and has an incidence of 4.9 to 32.7%.<sup>[2,3]</sup> Postoperative stiffness is known to be related to contracture or atrophy of the ligamentous and muscular structures, rotator cuff weakness, inflammation of the subacromial bursa, postoperative adhesions, and capsular contracture.<sup>[2,3]</sup> Prolonged postoperative immobilization, ineffective physical therapy, diabetes mellitus, and shoulder osteoarthritis are among the most common ethological factors for the development of postoperative shoulder stiffness.<sup>[3-6]</sup> This problem impairs patient satisfaction

and clinical outcomes, and consequently some of these patients require revision surgeries.<sup>[7-9]</sup>

There are relatively few studies available on the management of stiffness. Conservative methods are primarily used, and most postoperative stiffness problems can be healed with proper rehabilitation programs or steroid injections. However, some cases are resistant to these therapies and eventually require arthroscopic release.<sup>[5]</sup>

Prolotherapy is an injection-based regenerative method, which gains popularity in the treatment of musculoskeletal pathologies.<sup>[10]</sup> Hypertonic dextrose injections at varying concentrations lead to osmotic rupture in local cells.<sup>[11]</sup> Tissue around the injection area is irritated due to increased glucose levels in the extracellular matrix. Thus, an acute inflammatory response is initiated, which promotes fibroblast

proliferation and subsequent collagen synthesis, and produces healing and tissue renewal.<sup>[12-15]</sup> To the best of our knowledge, there are no clinical studies regarding the effects of prolotherapy injections in patients who have stiffness following failed shoulder arthroscopy.

In the present study, we aimed to investigate the effectiveness of prolotherapy injections for persistent shoulder pain and stiffness which occur after arthroscopic rotator cuff repair. Our hypothesis is that prolotherapy injections, which were successfully used before for similar indications, would alleviate stiffness and improve shoulder functions in failed shoulder surgery syndrome.

### PATIENTS AND METHODS

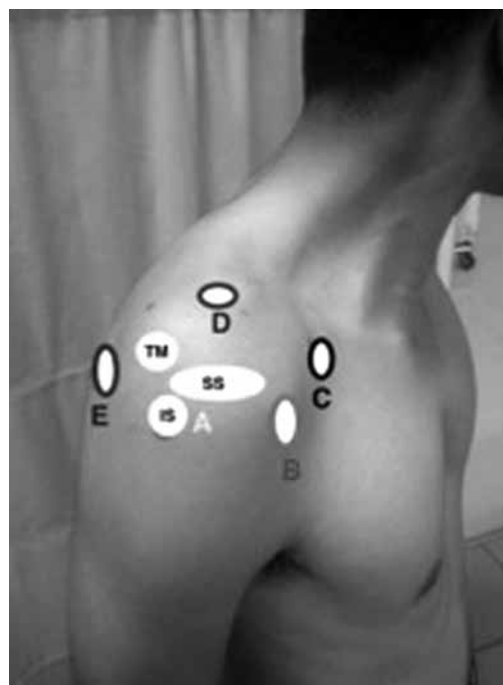
This prospective study included a total of 15 patients (5 males, 10 females; mean age  $49.4 \pm 10.7$  years; range, 33 to 71 years) who were referred to the orthopedics and sports medicine departments for the treatment of chronic shoulder pain and had stiffness which occurred after failed rotator cuff repair surgery between May 2014 and March 2016. A written informed consent was obtained from each patient. The study protocol was approved by the institutional Ethics Committee of Numune Hospital Training and Research Hospital (No: E-15-384). The study was conducted in accordance with the principles of the Declaration of Helsinki.

*Inclusion criteria were as follows:* Aged between 30 to 60 years, having arthroscopic rotator cuff repair and suffering from considerably due to loss of shoulder motion at all planes with pain and stiffness, having at least six months of complaints and being refractory to at least three months of conservative methods. All types of stiffness (with or without a re-tear of the repaired rotator cuff with degenerative arthritis and with deltoid injury)<sup>[16]</sup> based on ultrasonographic (USG) examinations were included. The diagnosis was clinically confirmed by physical examination and USG in all patients.

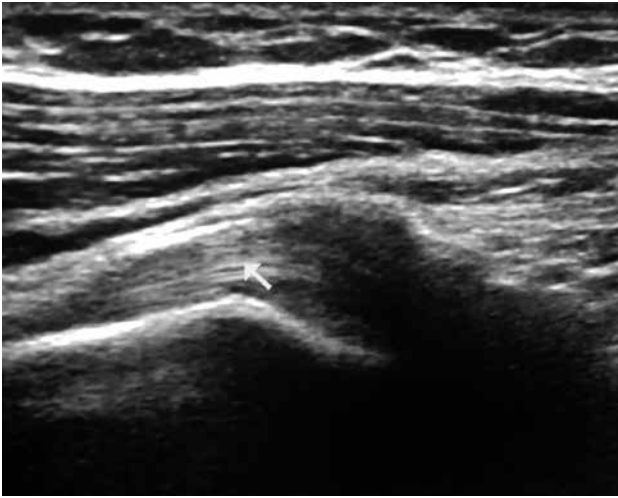Patients with rheumatic disease or other systemic inflammatory disease, osteomyelitis, history of chronic infection or active infection in the local treatment area, systemic infection, patients who received local corticosteroid injection within the past 12 weeks, who had hereditary or acquired bleeding tendency, and pregnancy were excluded from the study. Therefore, a total of 16 patients who met the inclusion criteria were enrolled in the study. However, one patient was excluded due to missing results (lost-to-follow-up at the final visit). Therefore, data including demographic and clinical characteristics of 15 patients were analyzed.

The prolotherapy sessions were applied in the sitting and upright position. The injected shoulder was positioned in the internal rotation and hyperextension position, the arm was positioned slightly behind its back, and the elbow was bent. The injections were performed under aseptic conditions with USG guidance. A 27-gauge needle was used for injections. Location and depth of the injection points were identified through USG. Five injection points were used (Figure 1).

- *Tuberculum majus:* 6 mL solution (5.4 mL of 15% dextrose and 0.6 mL lidocaine) was injected to the supraspinatus, infraspinatus, and teres minor insertions.
- *Coracoid process:* 4 mL solution (3.6 mL of 15% dextrose and 0.4 mL lidocaine) was injected to the pectoralis minor, coracobrachialis, and biceps brachii insertions with the shoulder in the neutral rotation.
- *Tuberculum minus:* 4 mL solution (3.6 mL of 15% dextrose and 0.4 mL lidocaine) was injected to the subscapularis insertion with the shoulder in external rotation and abduction/adduction.



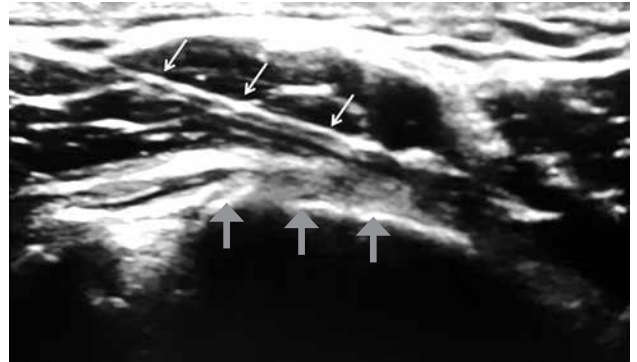
**Figure 1.** The injection points. (A) Tuberculum majus. (B) Tuberculum minus. (C) Coracoid. (D) Supraglenoid tubercle. (E) Subacromial bursae. SS: Supraspinatus; IS: Infraspinatus; TM: Teres minor.



**Figure 2.** An ultrasonographic image of rotator cuff tendon.

- *Supraglenoid tubercle*: 2 mL solution (3.6 mL of 15% dextrose and 0.4 mL lidocaine) was injected to the biceps long head.
- *Subacromial bursae*: 4 mL solution (3.6 mL of 25% dextrose and 0.4 mL lidocaine) was injected to the posterolateral aspect of acromion.

All patients were instructed to rest their shoulder, to refrain from any heavy lifting activity, and to apply hot water bags for 20 to 30 min every two or three hours for three days after every injection session. If the pain became unbearable, the patient was allowed taking 500 mg of acetaminophen up to four times per day. Other anti-inflammatory drugs were not allowed. The patients were also given a home-based exercise program in which passive range



**Figure 3.** Injection under the guidance of ultrasonography. Thin arrows indicate the needle, while thick arrows indicate supraspinatus tendon.

of motion exercises were performed within the first seven days, followed by stretching exercises three times a day up to 21 days following each injection session. Injections were repeated with an interval of 21 days and terminated, if the pain score as assessed by the visual analog scale (VAS) decreased to at least a quarter of the pre-injection values. The treatment was also terminated after a maximum six rounds of injections, or whenever the patient withdrew his/her consent.

Follow-up examinations were carried out in all patients independently by one of the coauthors at baseline, and Week 3, 6, and 12 after the initial treatment and the final follow-up visit for minimum one year. The patients were asked to report any adverse effects at each visit. The VAS for pain was used to evaluate the pain severity on a scale from 0 for no pain to 10 for severe pain. The clinical outcomes were classified as

**Table 1.** Baseline demographic and clinical characteristics of patients (n=16)

	n	Mean±SD
Age (year)		49.1±10.8
Gender		
Male	5	
Female	11	
Time of postoperative symptoms (months)		10.3±3.2
Side		
Right	9	
Left	7	
Follow-up (months)		17.3±4.3
Injection sessions		4.5±1.5
Stiffness type as determined on ultrasonography		
Without a retear of the repaired rotator cuff	13	
With a retear of the rotator cuff	3	
With degenerative arthritis	10	
With deltoid injury	6	

SD: Standard deviation.

excellent, good, fair, or poor. If the patient felt no pain during daily activities, sports or work, it was defined as excellent. Feeling less than 50% of the pain was defined as good, 50 to 75% as fair, and  $\geq 75\%$  as poor. The Western Ontario Rotator Cuff (WORC) Index was also used, which is one of the most common quality of life self-assessment scale for shoulder problems. This tool evaluates physical symptoms, sports, work and recreation habits, social and emotional well-being of patients. It consists of 21 questions which can be converted to a percentage score where 100% is the best possible score.<sup>[17,18]</sup> The reliability and validity of the WORC index have been previously shown in the evaluation of shoulder pain and stiffness.<sup>[18]</sup> The Shoulder Pain and Disability Index (SPADI) was also used for the evaluation of current shoulder pain and disability. This scale consists 13 items. The first five items are used to evaluate pain, while the remaining items assess disability.<sup>[19-21]</sup> The range of motion of the shoulder was also used in the evaluation using a goniometer (i.e., flexion, abduction, internal rotation, and external rotation). The reliability and validity of the SPADI for the evaluation of shoulder pain and stiffness have been shown by Hill et al.<sup>[20]</sup>

**Statistical analysis**

Statistical analysis was performed using the SPSS for Windows version 15.0 software (SPSS Inc., Chicago, IL, USA). Descriptive data were expressed in mean and standard deviation (SD), or median (min-max) and number and frequency. The Friedman test was used for the intragroup analyses. The SPSS/Sample Power program was used for post-hoc power. The Wilcoxon test with the Bonferroni adjustment was used for the post-hoc analysis. The Kuder-Richardson 20 (kr-20) reliability method was used to estimate the internal consistency. The Cronbach’s alpha was calculated for the internal consistency. A Cronbach’s alpha cut-off value of  $>0.80$  was set. A *p* value of  $<0.05$  was considered statistically significant.

**RESULTS**

Of all patients included, the mean duration of complaints was  $10.5 \pm 3.2$  months. The mean number of injection sessions was 4.46 and the mean follow-up was  $17.73 \pm 4.3$  months. Baseline demographic and clinical characteristics of the patients are given in Table 1.

The VAS, SPADI, and WORC Index scores and shoulder mobility significantly improved at all time points, compared to baseline values ( $p < 0.001$ ) (Table 2). Twelve patients (80%) reported excellent or good outcomes ( $n=7$  excellent;  $n=5$  good), while

**Table 2.** Clinical outcomes

	Month 0			Week 3			Week 6			Month 3			Month 12			p					
	Mean±SD	Median	Min-Max	Mean±SD	Median	Min-Max	Mean±SD	Median	Min-Max	Mean±SD	Median	Min-Max	Mean±SD	Median	Min-Max	Power	p				
VAS (0-10 mm)	8.1±1.3	9	6-9.8	5.7±2.0	6	2.1-9.2	4±2.1	3.1	1.3-7.9	3.1±2.5	3	0-7.5	2.1±2.7	0.8	0-7.8	0.999	<0.001†	WO-W3	<0.001	WO-W12	<0.001
WORC	26.6±12.5	23.8	9.5-52.9	47.6±12	47.4	23.8-63.4	67.2±15.8	69.6	36.2-88.2	79.3±18.3	84.6	47.4-97.6	84.4±18.1	92.8	49.8-99	0.999	<0.001†	<0.001	<0.001	<0.001	<0.001
SPADI	79.8±10.8	81.4	59-92.1	58.5±11.8	61.8	38.9-79.5	35.3±16.1	33	10.8-63.7	24.4±19.8	24.07	2.3-53.6	17.2±18.7	7.6	2.3-52.3	0.999	<0.001†	<0.001	<0.001	<0.001	<0.001
Flexion (°)	90±20.8	90	50-130	122.3±20.5	120	80-160	147.3±26.3	140	90-180	160±22.3	170	110-180	168.6±15.9	170	120-180	0.999	<0.001†	<0.001	<0.001	<0.001	<0.001
Abduction (°)	93.3±18.2	90	60-140	118.6±22.3	110	80-160	146±27	150	90-180	159.6±25.9	170	105-180	167±19.4	170	120-180	0.999	<0.001†	<0.001	<0.001	<0.001	<0.001
Int. rotation (°)	45±12.8	40	30-70	56.3±10.6	60	40-70	63.3±9.5	65	35-70	67.3±4.16	70	55-70	68.6±2.9	70	60-70	0.999	<0.001†	<0.001	<0.001	<0.001	<0.001
Ext. rotation (°)	57±17.2	60	30-90	68.6±2.9	70	45-90	75±15.6	80	40-90	80.6±10.6	90	65-90	84.3±9.7	90	65-90	0.999	<0.001†	<0.001	<0.001	<0.001	<0.001

SD: Standard deviation; Min: Minimum; Max: Maximum; VAS: Visual analog scale; WORC: Western Ontario Rotator Cuff; SPADI: Shoulder Pain and Disability Index. Int: Internal; Ext: External; Observed powers (Post-hoc powers) are over 80% for all variables. Intra-group analysis was performed using the Friedman test; † All binary comparisons of the measurements were found to be significantly different according to the post-hoc comparisons.

three patients (20%) reported fair or poor outcomes (n=1; n=2 poor). None of the patients experienced any serious complications (e.g., bleeding, infection, cellulitis, or septic joint). Only three patients had extreme pain one or two days after injections in the prolotherapy group, which was alleviated after two days of rest and local application of heat therapy. One patient had Grade 2 skin burns after the first injection due to the improper use of hot water bags and local anesthetic effect of the injections, and one patient had hypotension.

The internal consistency of the subscales of the WORC Index was 0.967 to 0.982 (Cronbach's alpha). The internal consistency of the subscales of the SPADI was 0.928 to 0.964 (Cronbach's alpha). Both of the questionnaires used in this study proved to be a valid and reliable tool to evaluate failed rotator cuff repair surgery.

## DISCUSSION

Postoperative stiffness is one of the most frequent postoperative complications which substantially decreases patients' satisfaction and comfort.<sup>[4]</sup> Some patients recover by simple treatment modalities, such as proper patient education and regular rehabilitation programs. However, many of them are unable to satisfy with them and, eventually require a revision surgery.<sup>[22]</sup> In the present study, we used prolotherapy injections for the treatment of refractory postoperative stiffness and found it to be an effective and safe method.

In daily practice, various physical treatment modalities are used for shoulder stiffness.<sup>[23]</sup> Physical therapy is helpful to relieve pain and return the functional motion to normal.<sup>[23]</sup> Non-steroidal anti-inflammatory drugs (NSAIDs) combined with physical therapy have been shown to be more effective than using NSAIDs alone.<sup>[24]</sup> Russell et al.<sup>[25]</sup> examined group exercise, individual physiotherapy, and home-based exercise alone. All study groups had better outcomes for pain relieving and returning the functions to normal within six weeks, six months, or on-year periods; however, group exercise resulted in a more rapid recovery of function, compared to other two groups.

Furthermore, it has been shown that heat application alters the viscoelastic properties of connective tissues, thereby improving shoulder stiffness.<sup>[26]</sup> Tensile stress has been demonstrated to considerably decrease with increasing soft tissue temperature to about 40 to 50°C, compared to what was recorded at 25°C.<sup>[27,28]</sup> Leung and Cheing<sup>[29]</sup> investigated the effectiveness of deep and surface heat application in patients with shoulder

stiffness and they found significant improvements in both groups for shoulder functions and pain severities. Physical therapy with aggressive passive stretching or dynamic bracing is considered the first-line treatment option for stiffness, which is supported by the existing literature.<sup>[30,31]</sup> However, many of the patients in these studies had idiopathic and post-injury etiologies and, therefore, patients with postoperative stiffness had worse outcomes.<sup>[16,32]</sup>

Many surgeons consider surgical approach for shoulder stiffness, when a six-month conservative treatment fails to restore a painless shoulder.<sup>[33]</sup> Arthroscopic capsular release is the most preferred option for shoulder stiffness.<sup>[22,34-36]</sup> There is an abundance of literature on the treatment of shoulder stiffness due to different etiologies (i.e., idiopathic, post-injury, and postoperative).<sup>[34-36]</sup> Warner et al.<sup>[22]</sup> used arthroscopic release in the treatment of postoperative shoulder stiffness and reported successful results in the functional scores and in the range of shoulder motions. Holloway et al.<sup>[36]</sup> also investigated outcomes of arthroscopic capsular release in the treatment of stiff shoulder (i.e., idiopathic, postoperative, and post-fracture origin) after a mean follow-up of 20 months and obtained significant improvements in patients for pain relieving, satisfaction, and functional status. In the aforementioned study, the patients with postoperative stiff shoulder had significantly lower scores in pain, satisfaction, and functional status than those with an idiopathic or post-fracture etiology. Most of the studies which used arthroscopy for shoulder stiffness reported successful results. However, the success of postoperative stiffness was shown to be lower than stiffness due to other etiologies.

Arthroscopic capsular release seemed to be a unique method for postoperative stiffness refractory to conservative methods. There is limited evidence regarding the success of less invasive methods. In the present study, the patients with symptoms lasting for six months and refractory to three months of conservative methods were examined. We obtained similar results with the previous studies which used arthroscopy. In addition, 80% of the patients reported excellent and good outcomes. Thus, prolotherapy injection method can be a considerable alternative to surgery owing to its less invasive nature, treatment success, early rehabilitation, and less complications.

Although surgical management of a rotator cuff tear has been well-defined in the literature, its postoperative outcomes have been less studied. Failure of tendon healing after rotator cuff repair has been

achieved in 20% of cases with shoulder stiffness being the most common reason for the failure.<sup>[37-39]</sup> Stiffness may arise from postoperative immobilization, patient's inability to comply with physical therapy, or associated shoulder osteoarthritis.<sup>[5,40]</sup> Shoulder stiffness may also present with rotator cuff and deltoid tears. The main factor in the selection of the most optimal treatment modality for shoulder stiffness is to identify the underlying etiology. Four types of stiffness may occur after rotator cuff repair: (i) stiffness without a re-tear of the repaired rotator cuff, (ii) stiffness with a re-tear of the repaired rotator cuff, (iii) stiffness with untreated osteoarthritis, and (iv) stiffness with nerve or deltoid injury.<sup>[16]</sup> The patients in the present study had operations between six and 16 months earlier and were refractory to conservative treatment. In the late period of surgery, degenerative arthritis was observed in 10, rotator cuff rupture in three, and deltoid tendon injury in six patients. Of note, most patients with postoperative stiffness can be healed with appropriate rehabilitation programs in the early period. Since inflammation is a part of the underlying mechanism, prolotherapy cannot be used in the treatment of acute conditions. Therefore, in the literature, prolotherapy has been used in the treatment of chronic joint-ligament problems. It has been known that most patients with postoperative stiffness can be healed with appropriate rehabilitation programs in the acute period. Therefore, in the present study, we included the patients who were refractory to rehabilitation programs and who had operations at least six months earlier. Based on the results of the present study, we suggest that rehabilitation programs should be used in the early period and prolotherapy injections should be used in patients who are refractory to these treatments and in chronic stage.

On the other hand, there is limited evidence regarding the treatment options other than surgery in the treatment of shoulder stiffness in the literature. Intra-articular corticosteroid injections were used in some other shoulder indications including adhesive capsulitis, impingement syndrome, and rotator cuff syndrome.<sup>[41]</sup> Although corticosteroid injections were successful in these conditions, there were some concerns about the use of corticosteroid injections, including the possibility of rotator cuff tendon ruptures, infections in the subacromial space, and glenohumeral joint.<sup>[42,43]</sup> Corticosteroid injections can be used in early period of postoperative stiffness; however, late stages of postoperative stiffness were found to be resistant to steroid injections.<sup>[43-45]</sup>

Prolotherapy injections in the treatment of other shoulder pathologies were previously reported in the literature.<sup>[46-49]</sup> Lee et al.<sup>[48]</sup> used prolotherapy injections in the treatment of non-traumatic refractory rotator cuff disease in patients who had complaints for three months. The authors performed three to eight sessions of injections and achieved a significant improvement in pain, disability, isometric strength, and shoulder motion. In another study, Bertrand et al.<sup>[46]</sup> used prolotherapy injections for rotator cuff tendinopathy in the randomized-controlled setting and obtained significant improvement in pain and functional scores. Prolotherapy can be used as a method of choice in many shoulder pathologies. In a previous study of our cohort, we used prolotherapy injections for the treatment of chronic rotator cuff lesions in the randomized-controlled setting to compare shoulder exercise protocols and observed that prolotherapy resulted in improved clinical outcomes than the control group.<sup>[50]</sup> In the present study, we also achieved significant improvements in patients with painful and stiff shoulder following arthroscopic rotator cuff repair compared to baseline. Significant improvements were also obtained in both three-month period and in longer terms, compared to pre-injection values. This finding indicates that effect of prolotherapy injections are not temporary, but sustainable for long-term, depending on healing and renewal of the tissues. Previous studies reporting the long-terms effects of prolotherapy in shoulder rotator cuff pathologies also support the findings of the present study.<sup>[48,50]</sup>

Different prolotherapy injections were used in previous studies. Bertrand et al.<sup>[46]</sup> used 25% dextrose and 0.1% lidocaine for painful rotator cuff tendinopathy, while Lee et al.<sup>[48]</sup> used a prolotherapy protocol involving a mixture of 8 mL 20% dextrose and 2 mL 1% lidocaine for rotator cuff disease. Rabago et al.<sup>[51]</sup> found that 25% dextrose injection to the joint space and 15% dextrose to the extra-articular soft tissue attachments yielded improved clinical outcomes. In their study, Reeves and Hassanein<sup>[52]</sup> used 25% intraarticular dextrose injection and 10% dextrose injection for the treatment of the anterior cruciate ligament laxity and reported that significant improvements were obtained with 25% concentration. Animal studies also demonstrated that dextrose concentrations lower than 10% stimulated cell and tissue proliferation, but did not affect the histological inflammatory reaction. Dextrose concentrations higher than 10% produce an osmotic (concentrated) gradient which stimulates the accumulation of growth factors and inflammatory cells, which in turn can initiate

the wound healing process.<sup>[15,53]</sup> In the present study, therefore, we used 15% dextrose and 0.2% lidocaine injections to the extra-articular structures and 25% dextrose and 0.2% lidocaine to the subacromial bursae and joint space as recommended by most studies, and obtained successful clinical results at painful and stiff shoulder after rotator cuff repair. To provide safer and more effective injections,<sup>[54]</sup> we carried out prolotherapy under the guidance of USG.

In the present study, three patients (20%) reported fair or poor outcomes (n=1 fair; n=2 poor). In these two patients with poor outcomes (patients with minimal changes in pain scores), shoulder mobility was improved considerably in one and minimally in the other. These two patients were eventually concluded to need surgery.

The major limitations of the present study are its small sample size, lack of a placebo-control group, and relatively shorter follow-up period. Therefore, we recommend further large-scale and long-term, prospective randomized-controlled studies to establish a conclusion.

In conclusion, to the best of our knowledge, there is no study investigating the effect of an injection method on the treatment of refractory postoperative stiffness. Therefore, the present study is the first could be a first in this virgin field of research. Our study results show that shoulder functions, pain severity, and patient satisfaction substantially improve with prolotherapy injections. Based on these results, we consider prolotherapy a successful and promising non-operative treatment option for painful and stiff shoulder following arthroscopic rotator cuff repair.

#### Declaration of conflicting interests

The authors declared no conflicts of interest with respect to the authorship and/or publication of this article.

#### Funding

The authors received no financial support for the research and/or authorship of this article.

## REFERENCES

1. Pham TT, Bayle Iniguez X, Mansat P, Maubisson L, Bonneville N. Postoperative pain after arthroscopic versus open rotator cuff repair. A prospective study. *Orthop Traumatol Surg Res* 2016;102:13-7.
2. Seo SS, Choi JS, An KC, Kim JH, Kim SB. The factors affecting stiffness occurring with rotator cuff tear. *J Shoulder Elbow Surg* 2012;21:304-9.
3. Huberty DP, Schoolfield JD, Brady PC, Vadala AP, Arrigoni P, Burkhart SS. Incidence and treatment of postoperative stiffness following arthroscopic rotator cuff repair. *Arthroscopy* 2009;25:880-90.
4. Brislin KJ, Field LD, Savoie FH. Complications after arthroscopic rotator cuff repair. *Arthroscopy* 2007;23:124-8.
5. Warner JJ, Greis PE. The treatment of stiffness of the shoulder after repair of the rotator cuff. *Instr Course Lect* 1998;47:67-75.
6. Debeyre J, Patie D, Elmelik E. Repair of ruptures of the rotator cuff of the shoulder. *J Bone Joint Surg [Br]* 1965;47:36-42.
7. Ruiz-Suarez M, Barber FA. Postoperative pain control after shoulder arthroscopy. *Orthopedics* 2008;31:1130.
8. Tashjian RZ, Bradley MP, Tocci S, Rey J, Henn RF, Green A. Factors influencing patient satisfaction after rotator cuff repair. *J Shoulder Elbow Surg* 2007;16:752-8.
9. Shamsudin A, Lam PH, Peters K, Rubenis I, Hackett L, Murrell GA. Revision versus primary arthroscopic rotator cuff repair: a 2-year analysis of outcomes in 360 patients. *Am J Sports Med* 2015;43:557-64.
10. Ersen O, Koca K, Akpancar S, Seven MM, Akyildiz F, Yildiz Y, et al. A randomized-controlled trial of prolotherapy injections in the treatment of plantar fasciitis. *Turk J Phys Med Rehab* 2018;64:59-65.
11. Di Paolo S, Gesualdo L, Ranieri E, Grandaliano G, Schena FP. High glucose concentration induces the overexpression of transforming growth factor-beta through the activation of a platelet-derived growth factor loop in human mesangial cells. *Am J Pathol* 1996;149:2095-106.
12. Rabago D, Slattengren A, Zgierska A. Prolotherapy in primary care practice. *Prim Care* 2010;37:65-80.
13. Reeves KD, Fullerton BD, Topol, G. Evidence-based regenerative injection therapy (prolotherapy) in sports medicine. In: Seidenberg PH, Beutler A, editors. *The Sports Medicine Resource Manual*. Amsterdam: Saunders (Elsevier), 2008; p. 611-9.
14. Murphy M, Godson C, Cannon S, Kato S, Mackenzie HS, Martin F, et al. Suppression subtractive hybridization identifies high glucose levels as a stimulus for expression of connective tissue growth factor and other genes in human mesangial cells. *J Biol Chem* 1999;274:5830-4.
15. Jensen KT, Rabago DP, Best TM, Patterson JJ, Vanderby R Jr. Response of knee ligaments to prolotherapy in a rat injury model. *Am J Sports Med* 2008;36:1347-57.
16. Harryman DTLM II, Rozencwaig R. The stiff shoulder. In: Rockwood CA Jr, Masten FA III, editors. *The Shoulder*. 2nd ed. Philadelphia: WB Saunders; 1998. p. 1064-112.
17. El O, Bircan C, Gulbahar S, Demiral Y, Sahin E, Baydar M, et al. The reliability and validity of the Turkish version of the Western Ontario Rotator Cuff Index. *Rheumatol Int* 2006;26:1101-8.
18. Wessel J, Razmjou H, Mewa Y, Holtby R. The factor validity of the Western Ontario Rotator Cuff Index. *BMC Musculoskelet Disord* 2005;6:22.
19. Bumin G, Tüzün EH, Tonga E. The Shoulder Pain and Disability Index (SPADI): Cross-cultural adaptation, reliability, and validity of the Turkish version. *J Back Musculoskelet Rehabil* 2008;21:57-62.
20. Hill CL, Lester S, Taylor AW, Shanahan ME, Gill TK. Factor structure and validity of the shoulder pain and disability index in a population-based study of people with shoulder symptoms. *BMC Musculoskelet Disord* 2011;12:8.

21. Kirkley A, Alvarez C, Griffin S. The development and evaluation of a disease-specific quality-of-life questionnaire for disorders of the rotator cuff: The Western Ontario Rotator Cuff Index. *Clin J Sport Med* 2003;13:84-92.
22. Warner JJ, Allen AA, Marks PH, Wong P. Arthroscopic release of postoperative capsular contracture of the shoulder. *J Bone Joint Surg [Am]* 1997;79:1151-8.
23. Hsu JE, Anakwenze OA, Warrender WJ, Abboud JA. Current review of adhesive capsulitis. *J Shoulder Elbow Surg* 2011;20:502-14.
24. Dudkiewicz I, Oran A, Salai M, Palti R, Pritsch M. Idiopathic adhesive capsulitis: long-term results of conservative treatment. *Isr Med Assoc J* 2004;6:524-6.
25. Russell S, Jariwala A, Conlon R, Selfe J, Richards J, Walton M. A blinded, randomized, controlled trial assessing conservative management strategies for frozen shoulder. *J Shoulder Elbow Surg* 2014;23:500-7.
26. Rennie DA, Michlovitz SL. Biophysical principles of heating and superficial heating agents. In: Michlovitz SL, editor. *Thermal agent in rehabilitation*. 3rd ed. Philadelphia: FA Davis Co.; 1996. p. 107-35.
27. Hardy M, Woodall W. Therapeutic effects of heat, cold, and stretch on connective tissue. *J Hand Ther* 1998;11:148-56.
28. Lehmann JF, Masock AJ, Warren CG, Koblanski JN. Effect of therapeutic temperatures on tendon extensibility. *Arch Phys Med Rehabil* 1970;51:481-7.
29. Leung MS, Cheing GL. Effects of deep and superficial heating in the management of frozen shoulder. *J Rehabil Med* 2008;40:145-50.
30. Ando A, Sugaya H, Hagiwara Y, Takahashi N, Watanabe T, Kanazawa K, et al. Identification of prognostic factors for the nonoperative treatment of stiff shoulder. *Int Orthop* 2013;37:859-64.
31. Shaffer B, Tibone JE, Kerlan RK. Frozen shoulder. A long-term follow-up. *J Bone Joint Surg [Am]* 1992;74:738-46.
32. Warner JJ. Frozen Shoulder: Diagnosis and Management. *J Am Acad Orthop Surg* 1997;5:130-40.
33. Bhatia S, Mather RC, Hsu AR, Ferry AT, Romeo AA, Nicholson GP, et al. Arthroscopic management of recalcitrant stiffness following rotator cuff repair: A retrospective analysis. *Indian J Orthop* 2013;47:143-9.
34. Trsek D, Cicak N, Zunac M, Klobucar H. Functional results and patient satisfaction after arthroscopic capsular release of idiopathic and post-traumatic stiff shoulder. *Int Orthop* 2014;38:1205-11.
35. Nicholson GP. Arthroscopic capsular release for stiff shoulders: effect of etiology on outcomes. *Arthroscopy* 2003;19:40-9.
36. Holloway GB, Schenk T, Williams GR, Ramsey ML, Iannotti JP. Arthroscopic capsular release for the treatment of refractory postoperative or post-fracture shoulder stiffness. *J Bone Joint Surg [Am]* 2001;83:1682-7.
37. Collin P, Abdullah A, Kherad O, Gain S, Denard PJ, Lädermann A. Prospective evaluation of clinical and radiologic factors predicting return to activity within 6 months after arthroscopic rotator cuff repair. *J Shoulder Elbow Surg* 2015;24:439-45.
38. Goldberg BA, Scarlat MM, Harryman DT. Management of the stiff shoulder. *J Orthop Sci* 1999;4:462-71.
39. Tauro JC. Stiffness and rotator cuff tears: incidence, arthroscopic findings, and treatment results. *Arthroscopy* 2006;22:581-6.
40. Vezeridis PS, Goel DP, Shah AA, Sung SY, Warner JJ. Postarthroscopic arthrofibrosis of the shoulder. *Sports Med Arthrosc Rev* 2010;18:198-206.
41. Gasparre G, Fusaro I, Galletti S, Volini S, Benedetti MG. Effectiveness of ultrasound-guided injections combined with shoulder exercises in the treatment of subacromial adhesive bursitis. *Musculoskelet Surg* 2012;96:57-61.
42. Zhang J, Keenan C, Wang JH. The effects of dexamethasone on human patellar tendon stem cells: implications for dexamethasone treatment of tendon injury. *J Orthop Res* 2013;31:105-10.
43. Hiemstra LA, Macdonald PB, Froese W. Subacromial infection following corticosteroid injection. *J Shoulder Elbow Surg* 2003;12:91-3.
44. Franceschi F, Papalia R, Palumbo A, Vasta S, Maffulli N, Denaro V. Management of postoperative shoulder stiffness. *Sports Med Arthrosc Rev* 2011;19:420-7.
45. Shin SJ, Do NH, Lee J, Ko YW. Efficacy of a Subacromial Corticosteroid Injection for Persistent Pain After Arthroscopic Rotator Cuff Repair. *Am J Sports Med* 2016;44:2231-6.
46. Bertrand H, Reeves KD, Bennett CJ, Bicknell S, Cheng AL. Dextrose Prolotherapy Versus Control Injections in Painful Rotator Cuff Tendinopathy. *Arch Phys Med Rehabil* 2016;97:17-25.
47. Seven MM, Koca K, Akpancar S, Turkkan S, Uysal B, Yildiz Y, et al. Promising results of prolotherapy in an elderly male with bilateral partial rotator cuff lesions. *BMMR* 2016;48: In press. [Access: May 23, 2016]
48. Lee DH, Kwack KS, Rah UW, Yoon SH. Prolotherapy for Refractory Rotator Cuff Disease: Retrospective Case-Control Study of 1-Year Follow-Up. *Arch Phys Med Rehabil* 2015;96:2027-32.
49. Akpancar S, Seven MM, Tuzun HY, Gurer L, Ekinci S. Current concepts of prolotherapy in orthopedic surgery. *Arch Trauma Res* 2017;6:e40447.
50. Seven MM, Ersen O, Akpancar S, Ozkan H, Turkkan S, Yildiz Y, et al. Effectiveness of prolotherapy in the treatment of chronic rotator cuff lesions. *Orthop Traumatol Surg Res* 2017;103:427-33.
51. Rabago D, Mundt M, Zgierska A, Grettie J. Hypertonic dextrose injection (prolotherapy) for knee osteoarthritis: Long term outcomes. *Complement Ther Med* 2015;23:388-95.
52. Reeves KD, Hassanein KM. Long-term effects of dextrose prolotherapy for anterior cruciate ligament laxity. *Altern Ther Health Med* 2003;9:58-62.
53. Jensen KT, Rabago DP, Best TM, Patterson JJ, Vanderby R Jr. Early inflammatory response of knee ligaments to prolotherapy in a rat model. *J Orthop Res* 2008;26:816-23.
54. Louis LJ. Musculoskeletal ultrasound intervention: principles and advances. *Radiol Clin North Am* 2008;46:515-33.