

Meralgia paresthetica caused by inguinal lymphadenopathy related to tinea pedis infection: A case report

Kardelen Gencer Atalay , Esra Giray , Günay Yolcu , İlker Yağcı 

Department of Physical Medicine and Rehabilitation, Marmara University School of Medicine, Istanbul, Turkey

Received: March 15, 2019 Accepted: May 30, 2019 Published online: February 26, 2020

ABSTRACT

Mechanical compression at any point along the lateral femoral cutaneous nerve (LFCN) may result in meralgia paresthetica (MP). A 54-year-old male patient presented with pain and tingling on the anterolateral side of thigh. After excluding other causes of pain radiating to legs, he was diagnosed with MP. Inguinal lymphadenopathy which caused the compression of LFCN was found on ultrasonographic examination. Tinea pedis infection was also identified during the detailed investigation for lymphadenopathy. Associated MP symptoms partially resolved immediately after ultrasound-guided LFCN block and a complete recovery was achieved after the treatment of tinea pedis.

Keywords: Meralgia paresthetica, tinea pedis, ultrasound.

Meralgia paresthetica (MP) is a mononeuropathy of the lateral femoral cutaneous nerve (LFCN) resulting in pain, paresthesia, and numbness at the anterolateral side of the affected thigh.^[1] The LFCN originates from the lumbar plexus and has root innervation from L2-3. The nerve passes through the pelvis along the lateral border of the psoas muscle and, with a wide variation, mostly reaches to the thigh from near the anterior superior iliac spine (ASIS) under the inguinal ligament. Associated MP symptoms may occur with mechanical compression along the anatomical course of this nerve, most commonly as it exits pelvis nearby ASIS.^[1-3] There are rare causes as compressive factors like mass, hematoma, and urinary stone.^[4-7] Although a detailed medical history and physical examination are usually enough for the diagnosis, ultrasonography (US) and nerve conduction studies are also useful to identify the etiological factor and differential diagnosis.^[8]

Herein, we report a case of MP caused by inguinal lymphadenopathy related to tinea pedis infection.

CASE REPORT

A 54-year-old man presented with a three-year history of pain and tingling sensation on the anterolateral

side of his left thigh. Symptoms were increased while standing and walking. Pregabalin was started and gradually increased to 450 mg/day one year ago, and complaints were reported to decrease. However, for the last one month, symptoms were aggravated. There was no sign of chronic disease in his past medical history. The range of motion of the lumbar and bilateral hip, muscle strength and deep tendon reflexes of both lower extremities were found to be normal upon physical examination. Lateral pelvic compression test results were positive. The Tinel's sign around the ASIS was negative. Erythrocyte sedimentation rate (ESR) was slightly increased (23 mm/h), whereas other laboratory test results were found to be within the normal range. Magnetic resonance imaging of lumbar and coxa-femoral joints did not reveal other possible causes of the symptoms. A solid heterogenic lesion which caused the compression of LFCN was noticed during the ultrasonographic examination (Figure 1). It was painful with sonopalpation. The LFCN was found to be thickened, compared to the right side (Figure 2). The patient was consulted to the radiology department, and the lesion was considered a reactive lymph node. Ultrasound-guided LFCN block with 1 mL betamethasone and 4 mL 0.5% bupivacaine was

Corresponding author: Kardelen Gencer Atalay, MD. Marmara Üniversitesi Pendik Eğitim ve Araştırma Hastanesi, Fiziksel Tıp ve Rehabilitasyon Kliniği, 34899 Pendik, İstanbul, Türkiye. e-mail: kardelengencer@gmail.com

Cite this article as:

Gencer Atalay K, Giray E, Yolcu G, Yağcı İ. Meralgia paresthetica caused by inguinal lymphadenopathy related to tinea pedis infection: A case report. Turk J Phys Med Rehab 2020;66(x):i-iii.

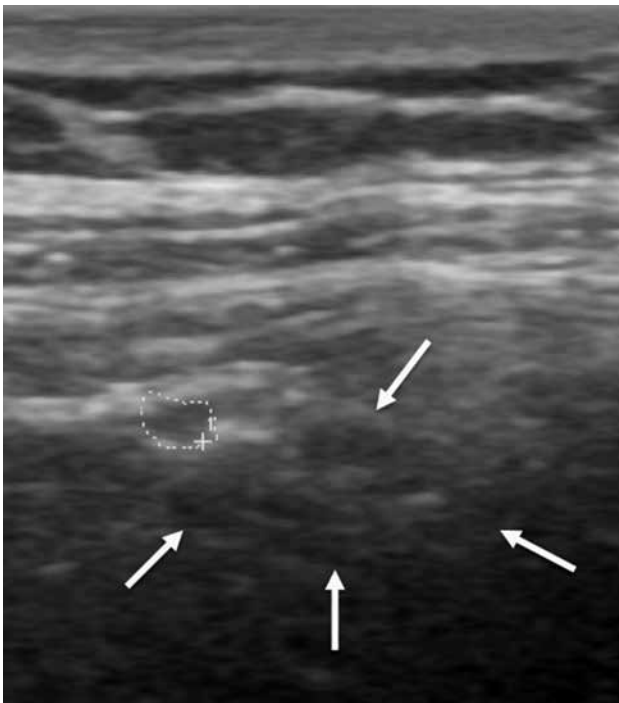


Figure 1. Longitudinal sonographic image demonstrating the lateral femoral cutaneous nerve (dashed line circle) and the inguinal lymphadenopathy (arrows).

performed, and immediately after the injection, the pain level decreased from 8 to 3 using the numeric rating scale (NRS). A pruritic lesion at his left thumb was noticed during the detailed examination for the infectious state, and the patient was consulted to the dermatology department. Combination of oral and topical anti-fungal therapy was started with the diagnosis of tinea pedis. One month later, the patient's

pain level decreased to 1, and ESR was found to be within normal values (7 mm/h). The reactive lymph nodes were found to be smaller in ultrasonographic evaluation. At the third month, tinea pedis infection was entirely resolved, and the pain level of the patient was 0. Pregabalin dosage was gradually decreased and discontinued. The complete response to pain level remained unchanged at the sixth-month control. A written informed consent was obtained from the patient.

DISCUSSION

In this case report, the etiological factor of MP was found to be the inguinal reactive lymph nodes related to tinea pedis infection. After successful therapy of the fungal infection, swollen lymph nodes were regressed, while the patient's need for pain therapy disappeared. Although rare causes such as mass, hematoma, and urinary stones were shown to result in MP by mechanical compression of LFCN,^[4-7] it was noteworthy to find out a distant pathology such as tinea pedis infection as the initiative factor for MP. To the best of our knowledge, this is the first report showing the relevance between inguinal lymphadenopathy and MP in the literature. The initial approach to the patient was to identify the pathology and, then, an LFCN block was performed to confirm the diagnosis. Ultrasonography had a crucial role for both purposes. Moreover, US-guided LFCN block was also an important step for the treatment of symptoms. Accordingly, US was previously used to identify the etiology and manage the symptoms of MP in several cases.^[9,10] Ultrasonography-guided LFCN block using local anesthetics with or without

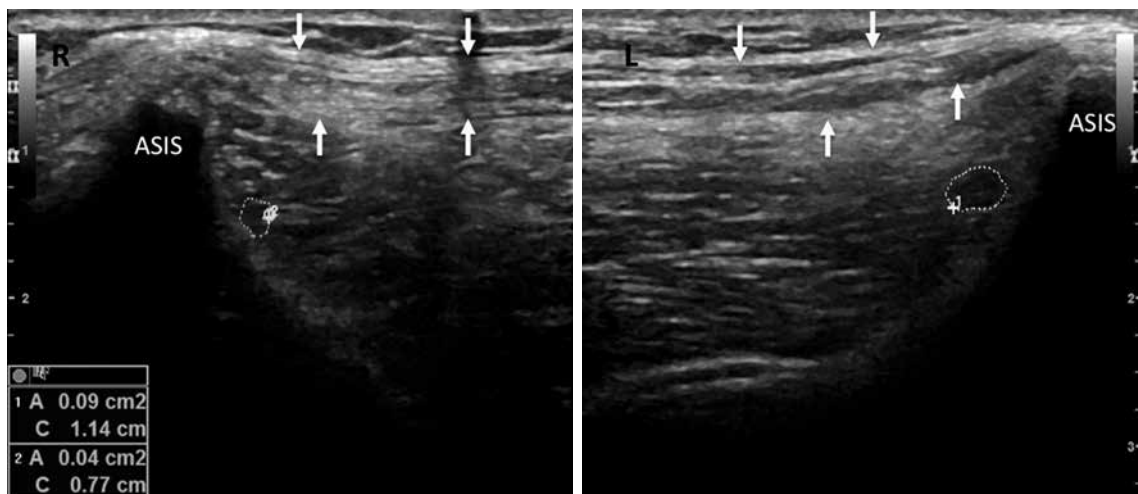


Figure 2. Transverse sonographic image demonstrating the lateral femoral cutaneous nerve (dashed line circles) and the inguinal ligament (arrows).

R: Right; L: Left; ASIS: Anterior superior iliac spine.

steroid was found to provide long-term benefits in MP symptoms.^[11,12] Ultrasonography has also advantages in the visualization of anatomical variations; thus, it can improve the procedural accuracy for targeting the LFCN.^[13] In this report, the main reason for the success of the treatment was finding and eliminating the cause of mechanical compression on the LFCN. However, it is also known that MP symptoms may persist even after mechanical compression is removed. In refractory cases, ultrasonography-guided radiofrequency ablation of LFCN can be applied.^[14-16] Surgical interventions can also be considered in cases unresponsive to conservative treatment.^[17] There was no need for radiofrequency ablation or surgical intervention in this case.

In conclusion, MP symptoms may be caused by inguinal lymph nodes related to tinea pedis infection and the entire examination of related body areas has an important role. In addition, the importance of US-guidance is revisited and illustrated as a useful tool for the diagnosis, treatment, and follow-up.

Declaration of conflicting interests

The authors declared no conflicts of interest with respect to the authorship and/or publication of this article.

Funding

The authors received no financial support for the research and/or authorship of this article.

REFERENCES

- Cheatham SW, Kolber MJ, Salamh PA. Meralgia paresthetica: a review of the literature. *Int J Sports Phys Ther* 2013;8:883-93.
- Grossman MG, Ducey SA, Nadler SS, Levy AS. Meralgia paresthetica: diagnosis and treatment. *J Am Acad Orthop Surg* 2001;9:336-44.
- Patijn J, Mekhail N, Hayek S, Lataster A, van Kleef M, Van Zundert J. Meralgia Paresthetica. *Pain Pract* 2011;11:302-8.
- Taşdemir S, Ulaş ÜH, Yücel M, Çetiz A. Meralgia paresthetica after the fragmentation of renal stone using extracorporeal shock wave lithotripsy: a case report. *Acta Neurol Belg* 2016;116:423-4.
- Noh KH, Kim DS, Shin JH. Meralgia paresthetica caused by a pancreatic pseudocyst. *Muscle Nerve* 2015;52:684-5.
- Ramírez Huaranga MA, Ariza Hernández A, Ramos Rodríguez CC, González García J. What meralgia paresthetica can hide: renal tumor as an infrequent cause. *Reumatol Clin* 2013;9:319-21.
- Yi TI, Yoon TH, Kim JS, Lee GE, Kim BR. Femoral neuropathy and meralgia paresthetica secondary to an iliacus hematoma. *Ann Rehabil Med* 2012;36:273-7.
- Harney D, Patijn J. Meralgia paresthetica: diagnosis and management strategies. *Pain Med* 2007;8:669-77.
- Chang KV, Mezian K, Naňka O, Wu WT, Lou YM, Wang JC, et al. Ultrasound Imaging for the Cutaneous Nerves of the Extremities and Relevant Entrapment Syndromes: From Anatomy to Clinical Implications. *J Clin Med* 2018;7. pii: E457.
- Onat SS, Ata AM, Ozcakar L. Ultrasound-guided diagnosis and treatment of meralgia paresthetica. *Pain Physician* 2016;19:E667-9.
- Tagliafico A, Serafini G, Lacelli F, Perrone N, Valsania V, Martinoli C. Ultrasound-guided treatment of meralgia paresthetica (lateral femoral cutaneous neuropathy): technical description and results of treatment in 20 consecutive patients. *J Ultrasound Med* 2011;30:1341-6.
- Klauser AS, Abd Ellah MM, Halpern EJ, Sporer I, Martinoli C, Tagliafico A, et al. Meralgia paraesthetica: Ultrasound-guided injection at multiple levels with 12-month follow-up. *Eur Radiol* 2016;26:764-70.
- Palamar D, Terlemez R, Akgun K. Ultrasound-guided diagnosis and injection of the lateral femoral cutaneous nerve with an anatomical variation. *Pain Pract* 2017;17:1105-8.
- Fowler IM, Tucker AA, Mendez RJ. Treatment of meralgia paresthetica with ultrasound-guided pulsed radiofrequency ablation of the lateral femoral cutaneous nerve. *Pain Pract* 2012;12:394-8.
- Ghai B, Dhiman D, Loganathan S. Extended duration pulsed radiofrequency for the management of refractory meralgia paresthetica: a series of five cases. *Korean J Pain* 2018;31:215-20.
- Philip CN, Candido KD, Joseph NJ, Crystal GJ. Successful treatment of meralgia paresthetica with pulsed radiofrequency of the lateral femoral cutaneous nerve. *Pain Physician* 2009;12:881-5.
- Ataizi ZS, Ertilav K, Ercan S. Surgical options for meralgia paresthetica: long-term outcomes in 13 cases. *Br J Neurosurg* 2019;33:188-91.